

Platelet-rich plasma and its effect in bone regeneration in mandibular fractures. Controlled clinical trial

Guadalupe Castillo-Cardiel¹, Víctor Manuel Medina-Quintana², Mario Lomelí-Enríquez¹, Fabiola Medrano-Muñoz³, Celia Guerrero-Velázquez⁴, Carmen Karina Contreras-López³, Clotilde Fuentes-Orozco³, Leire Irusteta-Jiménez³, Luis Rodrigo Michel-Espinoza³ and Alejandro González-Ojeda³

¹Department of Maxillofacial Surgery; ²Department of Plastic and Reconstructive Surgery; ³Biomedical Research Unit 02, High Specialty Medical Unit, Specialty Hospital, Centro Médico Nacional de Occidente, Instituto Mexicano del Seguro Social, Mexico; ⁴Department of Comprehensive Dental Clinics, Institute of Research in Dentistry, CUCS Universidad de Guadalajara. Guadalajara, Jal., Mexico

Abstract

Background: At present, there is great interest in developing clinical applications of platelet-rich plasma (PRP) to enhance bone repair. **Aim:** The aim of the study was to assess bone regeneration (BR) in mandibular fractures, with the application of this adjuvant. **Methods:** A total of 20 patients with mandibular fractures were included in a randomized clinical trial. Patients of the experimental group ($n = 10$) were submitted to internal fracture reduction and administration of PRP, and patients of the control group ($n = 10$) were submitted to the same surgical procedure without plasma application. Radiologic assessment was made before and at 1st and 3rd months after surgery. X-rays were digitalized for analyze intensity and density as a reflection of BR. **Results:** The average age was 32 ± 11.3 years and 31.2 ± 8.48 years, respectively ($p = 0.76$). The radiographic intensity and density in the experimental group at the 1st and 3rd month were higher in contrast to the control group ($p < 0.005$). BR time was 3.7 ± 0.48 and 4.5 ± 0.52 weeks, respectively ($p = 0.002$). There was no morbidity related to the application of the PRP. **Conclusion:** The PRP increased the bone intensity and density in the fracture trace allowing BR and recovery in a shorter time than patients in which it was not used.

KEY WORDS: Platelet-rich plasma. Mandibular fractures. Bone regeneration.

Introduction

Trauma is defined as an injury, intentional or not, caused by abrupt exposure of the body to sources or concentrations of mechanical, chemical, thermal or radiant energy that surpass its margin of tolerance; it is a public health problem and an important cause of morbidity and mortality in people at reproductive age¹. Multiple trauma patients represent a challenge after the advent of high-speed transportation². Craniofacial fracture fundamental etiologic factors are motor

vehicle accidents, aggressions by third parties, trauma at home and sport and working accidents, and it is more common in young males³.

Mandibular fractures are among the most common facial traumas. A fracture can be caused by a direct or indirect mechanism, such as condylar fractures in symphyseal trauma⁴.

Their clinical presentation includes joint function impairment (impossibility to fully open or close the mouth), mandibular arch deformity (malocclusion), crepitus, displacement, abnormal mobility, swelling with tenderness, facial asymmetry (due to bone

Correspondence:

Alejandro González-Ojeda
Av. Belisario Domínguez, 1000
Col. Independencia
C. P. 44340, Guadalajara, Jal., Mexico
E-mail: avygail5@gmail.com

Date of reception: 20-04-2016
Date of acceptance: 19-05-2016
DOI: 10.24875/GMMM17000024

Gac Med Mex. 2017;153:421-426
Contents available at PubMed
www.gacetamedicademexico.com

fracture or dislocation), mucosal tear and paresthesia, dysesthesia or anesthesia of the lips due to inferior alveolar nerve lesion³. The clinical picture is suggestive and panoramic X-ray, or orthopantomography provides a detailed view. It enables the visualization of the entire mandible and teeth. The mandibular series includes the anteroposterior, Towne's and right and left lateral oblique views⁵.

At present, there is interest in the development of platelet-rich plasma (PRP) clinical applications to improve bone regeneration (BR), particularly in patients at risk of bone nonunion or with established poor bone union. In the USA, approximately 5–10% of fractures are associated delayed BR or bone nonunion^{6–9}.

The purpose of this study was to assess autologous PRP effectiveness as a simple method to increase BR in mandibular fractures.

Methods

Twenty patients from the Department of Maxillofacial Surgery of the High Specialty Medical Unit, Specialty Hospital of the Centro Médico Nacional de Occidente, at Guadalajara, Jalisco, Mexico, who required mandible angle fracture reduction and internal fixation, from either gender, of legal age, and who agreed to sign an informed consent, were included. The patients were randomized by means of closed envelopes to two groups: The study group, which was treated by applying PRP along the fracture line prior and following internal fixation, and the control group, which underwent the same procedure but without PRP being applied. Patients with diabetes, hypercholesterolemia, active smoking or collagen disease that might alter bone healing, or those with data consistent with infection located at the zone to be treated or whose fracture had occurred more than 10 days before the scheduled day for surgery were not included.

Radiographic BR (density and intensity) was measured at the fracture site, with baseline measurements taken before surgery and then at 1st and 3rd month. Consolidation time (substitution of the fracture with bone), the presence of complications, time of recovery and sequels were measured as well.

Procedures

For fracture repair assessment, serial radiographs of the study fracture site were taken, with orthopantomography scans being obtained at admission for baseline measurements and 4 and 12 weeks.

Measurements at a bone site with no fracture were also made. All radiographs were converted into digital images as standard procedure. The digitalized images were analyzed using the Kodak Dental Imaging 1D Scientific System software, version 3.5.4^{10–13}. The radiographs were presented on screen as magnified images; all of them were analyzed by an operator blinded to the experimental maneuver. On each image, using the mouse pointer, a quadrangle was traced enclosing the fracture line (region of interest), without surrounding bone or osteosynthesis material being included; the software makes the measurement at 10 points on average, called "bands," within the marked square (Fig. 1). The software makes the measurement at each band reflecting the radiographic intensity and density of the image, using pixels (minimum possible unit whereby any digital image is composed) as the measurement unit; a high-intensity value is represented as a light gray tone on the digital image and, conversely, a low-intensity value is represented as a dark gray tone on the digitalized image. At higher density and intensity, the assessed bone is considered to be of higher quality, it exhibits calcification and has better probabilities of healing^{10–12}.

Before the surgical intervention, an antimicrobial course was started with cefotaxime (1 g, intravenously every 8 h) in all patients. Surgery was performed within a period no longer than 5 days after admission. The sutures used were polydioxanone (PDS) 3–0 and 4–0 for inner tissues, and nylon 5–0 for external tissues. All patients were intervened using an external surgical approach (sub-angular) to prevent contamination of the fracture with oral microbial flora.

For the PRP preparation, 20 cc of peripheral venous blood were extracted in tubes with 3.8% sodium citrate as an anticoagulant and slow centrifugation was performed for no longer than 20 min (or $\times 450$ g [1800 rpm] for 8 min, according to PRGF System III, BTI, Vitoria-Gasteiz, Spain)^{13,14}. The purpose is to obtain a platelet precipitate, and using the established time and velocity parameters; platelets can be concentrated at the next cubic centimeter of plasma immediately above the red blood cell series. It is prepared minutes before its use in the operating room. To achieve platelet degranulation, they were activated with calcium chloride (50 μ l/ml of plasma); this reverses the anticoagulant effect that prevents coagulation by chelating calcium ions. Depending on its concrete application, this preparation is used, as in this case, directly at fluid state in order for coagulation to occur at the selected place. As an alternative, it can be left to coagulate

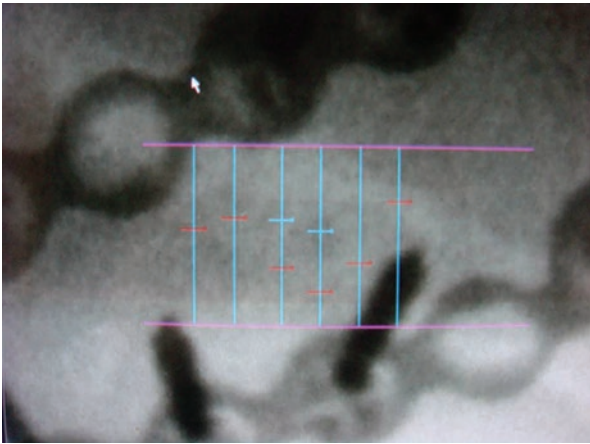


Figure 1. Software-assisted densitometric image analysis.

within the tube, or adequate container to then apply it predetermining its shape or suturing it to the tissue¹⁴⁻¹⁶.

The surgical procedure was carried out under general anesthesia. With the patient in the dorsal decubitus position, the procedure was initiated with external and intraoral surgical cleansing with 11% iodopovidone, after checking for the absence of allergies to the substance.

Intermaxillary fixation was then carried out with stainless steel wire, using an IVY-type cerclage. Wisdom-type sub-angular incision design at the affected side, 2 cm below the mandibular angle. Infiltration with 2% xylocaine plus epinephrine at a 1:200,000 dilution on the incision site. Then, an incision was made on the skin, taking care of adequate hemostasis and continuing with blunt dissection. The platysma muscle was then incised to locate the pterygomasseteric sling. Using a cautery, the periosteum was located and incised with a second scalpel. Deperiostization of the mandibular angle was carried out until the fracture line was located, leaving sufficient space at each side for the placement of miniplates. At this point of the intervention, the patients of the study group received the PRP at the bone ends of the fracture line according to the patient random assignment, with subsequent open reduction of the fracture until adequate fixation (Fig. 2) at the mandibular inferior region with 2.0 system Shyntes titanium compression plates, a three-orifice plate with three orifices being placed at each side of the fracture and one onto it using 2.0 × 12 mm bicortical screws. A 5-orifice 2.0 system Synthes titanium plate was placed at the superior region as tension plate, with two orifices placed at each side of the fracture and one onto it, fixating it with 2.0 × 8 mm unicortical screws. After fixation with miniplates, PRP was applied again to the fracture line.

Closure of the incision was performed at three planes, the first one with periosteum and muscular tissue apposition with PDS 3–0 with separate stitches, subcutaneous and dermal cell tissue apposition with PDS 4–0 with separate stitches and skin closure with subdermal nylon 4–0. All patients received dexamethasone (8 mg, intravenously) at the trans-surgical period to reduce the swelling.

The patients remained hospitalized during the post-operative period for 24 h. Cefotaxime was used as the recommended prophylactic antibiotic at a dose of 1 g intravenously every 8 h. Metamizole sodium was used as an analgesic at doses of 1 g intravenously every 8 h, as well as diclofenac, 75 mg by the intramuscular route every 12 h until 2 doses were completed. The intravenous solution used was 0.9% NaCl, 1000 ml every 12 h.

Medical treatment for the following 10 days at home was ciprofloxacin 500 mg tablets every 12 h and 500-mg acetaminophen tablets every 6 h.

A convenience sample size of 10 patients per group was established, since scientific previous experience on the subject, particularly with this type of fracture, is scarce or is related to the replacement of bone areas with PRP and bone grafts, or for the management of denture rest seats and implants.

The descriptive section of the statistical analysis presents the qualitative variables with crude numbers and proportions. The quantitative variables are presented as means ± standard error of the mean. At the inferential phase of analysis, qualitative variables were analyzed with the Chi-square test or Fisher's exact test, and quantitative variables, with Student's t-test for independent and small samples. Statistical significance was established at a $p < 0.05$.

Ethical considerations

The research protocol was approved by the Local Committee of Research and Ethics in Health Comité Local de Investigación y Ética en Salud with record number R-2007–1301-8. In addition, the study was conducted in compliance with the guidelines in matters of research in human beings of the general Statute of Health of Mexico. The patients who agreed to their inclusion in the study signed their consent for participation.

Results

We studied 3 females (15%) and 17 males (75%). Two females and 8 males were included in the

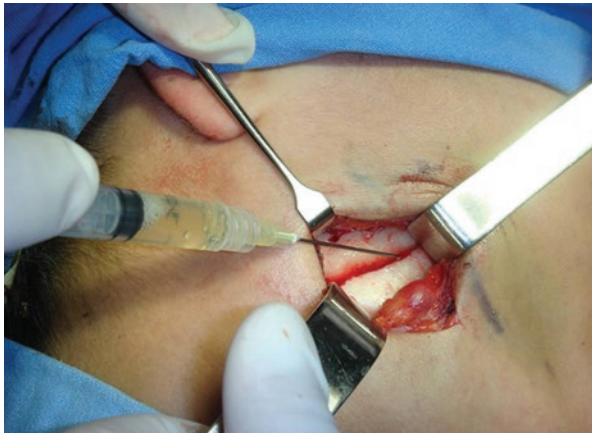

Figure 2. Platelet-rich plasma application on the fracture line before reduction and fixation.

experimental group; the rest comprised the control group ($p = 0.84$). In the experimental group, the age was 32 ± 11.3 years, and 31.2 ± 8.48 years for controls ($p = 0.76$). The place where the lesion occurred was analyzed, with 2 (10%) being found to have occurred at the workplace and the rest 18(90%) somewhere else. The lesion mechanism was aggression in 7 cases (35%), accidental falls in 6 (30%), motor vehicle accidents in 6 (30%), and not explained in 1 (5%). Mandibular angle fracture occurred on the right side in 8 patients (40%) and on the left side in 10 (50%), and it was bilateral in 2 (10%).

Bone intensity and density baseline determinations are shown in table 1. Intensity and density at the fracture line showed lower values than those obtained at an area of the mandible of the same patients without any lesion at all.

Radiographic studies 1 month after the surgical intervention showed an intensity of 123.08 ± 28.76 and density of 445.38 ± 382.09 in the cases, and an intensity of 103.33 ± 42.95 and density of 268.40 ± 168.22 for controls. This difference was statistically significant, as shown in table 2. At 3 months from the surgical intervention, radiographic evaluation showed an intensity of 154.65 ± 28.56 and density of 685.08 ± 745.78 in the PRP-treated group, and an intensity of 123.22 ± 33.94 and density of 494.61 ± 414.75 in the control group. These differences in bone healing were also statistically significant.

The time for fracture regeneration, with the lesion being assessed from the moment of surgery to regeneration was found in the fracture line, was 3.7 ± 0.48 weeks in the experimental group and 4.5 ± 0.52 weeks in the control group ($p = 0.002$).

No complications occurred. There was one sequel in the PRP-administered group and two sequels in the control group, all related to fractures in other facial sites, such as mandibular condyle, superior maxilla, and parasymphiseal region of the mandible.

Discussion

In Mexico, trauma is the fourth cause of death, with around 36,000 annual deaths according to data from the National Institute of Statistics and Geography¹⁷. Craniofacial trauma is quite common. In a study conducted at the Hospital Juárez de México, 221 cases were reported in 2 years (2007 and 2008), out of which 133 were maxillary fractures, which accounts for 68% of total cases; in addition, 28 dentoalveolar fractures (14%), 25 malar fractures (12%), 11 maxilla fractures (5%), and 4 panfacial fractures (2%) were reported¹⁸.

A retrospective study was conducted at the Hospital Central Militar de México where 41 patients with mandibular fractures were included, with most common causes found being urban violence (41%) and motor vehicle accidents (29%). In addition, the frequency of fracture site was analyzed, with the most repeated being the mandibular angle (33.8%), parasymphiseal fractures (30.8%), and mandibular ramus (10.7%)¹⁹. Given that our institution is a reference center, the reconstruction of this type of lesions is quite usual. We manage approximately 150 patients per year, the vast majority of them economically active young adults, with this representing one of the main causes of hospital stay in our department.

Facial fractures reduction and stabilization are two indispensable aspects to enable quick BR, recovery of the masticatory mechanics, decrease of facial sequels, and rapid reintegration to work activities.

With the use of PRP, we sought to reduce the BR time of a fracture using a technique that does not cause any harm to the patient, that is technically simple and has low cost, looking for beneficial results for both the patient's health and the institution by decreasing the time for recovery and patient disability leave.

PRP therapeutic use is a relatively new biotechnology that has been used to stimulate and accelerate the healing of soft and bone tissues²⁰. It has been applied in multiple specialties of medicine, including orthopedics, maxillofacial surgery, and plastic surgery, just to mention some. Notwithstanding, there is controversy in the literature about the benefits of this

procedure: Different authors have reported improvement in tissue healing and bone formation, while others have not found any advantage at all²⁰. These discrepancies are most likely due to a lack of standardization and definition of the different plasma preparations.

This study demonstrates that autologous PRP application at the mandible fracture site is a valid and effective method to induce BR and significantly accelerating it at the fracture site, without causing complications inherent to the procedure. All this was confirmed by statistically significant differences in radiographic density and intensity at 1st and 3rd month favoring the experimental group in comparison with the control group, as well as radiographic density that was similar to the normal bone at 3 months in those patients who had PRP applied.

There are three basic biological approaches that show promise as new technologies in fracture repair: The use of exogenous growth factors, mesenchymal cell therapy and gene therapy²¹⁻²⁴. Recently, treatments with PRP that were initially used in oral surgery to improve dental implants osteointegration have been reported²²⁻²⁵. In orthopedic surgery, PRP has been used and has cut in half the time of recovery of patients with muscle or tendon injuries or bone fractures; in coronary artery bypass grafting, as well as in the treatment of chronic ulcers²⁶⁻³⁰, platelet-derived growth factor has been shown to stimulate trabecular bone³¹ and human osteoblastic cells^{30,31} proliferation in studies *in vitro*; and PRP administration in combination with bone grafts favors faster bone integration and histomorphometrically denser BR³².

Growth factors are found in different tissues and cells, but studies have focused on platelets because they are relatively easy to obtain, have a half-life of 8–12 days and, in addition, they carry other proteins that are useful in tissue regeneration and repair, and are, therefore, considered a natural source of growth factors. The release of these factors is triggered by platelet activation and, thus, the amount of growth factors depends on the degree of platelet activation³³.

The use of PRP has become a therapeutic approach for the regeneration of multiple tissues. In 1998, Marx et al.²⁴ described a positive effect of PRP on BR and, since that moment, its clinical and surgical use for that purpose has increased. Its properties include that it is an autologous product, it induces angiogenesis, it is biocompatible, it promotes osteointegration and cell

Table 1. Bone intensity and density baseline measurements on normal bone and on the fracture line of all patients

	Baseline normal bone	Baseline fracture line	p
Intensity	138.7 ± 2.9	80.0 ± 2.3	0.000
Density	694.0 ± 14.1	222.8 ± 7.1	0.000

Values are expressed in pixels; normal bone measurements were made at the contralateral area of the fracture, and if the fracture was bilateral, they were taken outside the fracture lines.

Table 2. Mandibular fractures regeneration evolution with and without platelet-rich plasma

		With plasma	Without plasma	p
Measurements	Intensity	79.9 ± 1.3	80.0 ± 1.7	0.5
	Density	221.1 ± 8.4	227.1 ± 9.1	0.7
4 weeks	Intensity	123.0 ± 2.5	103.4 ± 7.8	0.000
	Density	445.4 ± 35.5	268.4 ± 15.1	0.000
12 weeks	Intensity	154.6 ± 3.7	123.2 ± 4.3	0.000
	Density	685.1 ± 96.2	494.6 ± 53.1	0.005

Values are expressed in pixels.

proliferation, it compacts grafts or biomaterials, thus facilitating their manipulation and reconstructions, it is reabsorbed and replaced once the tissue regeneration process is initiated, it creates a hemostatic and lymphatic bioseal, thus eliminating post-operative drainage and reducing edema, it accelerates soft tissue regeneration and initiates the osteogenesis cascade, it accelerates the tissue repair processes and promotes epithelization^{34,35}. In addition, it is important to differentiate between the functions of both substances have.

Conclusions

The results demonstrated that the radiographic density and intensity achieved in the experimental group at 1 month is very similar to that found for the control group at 3 months, this way improving BR and shortening the time for recovery. Furthermore, the radiographic density and intensity achieved in the experimental group at 3 months is similar to the density recorded in normal bone.

Acknowledgments

We thank Jaime Darío Mondragón-Espinoza, Ph.D., C Full-Time Research Professor, Universidad de Guadalajara, for his valuable support and participation for the development of this study. In much the same way,

we thank Fondo de Investigación en Salud for the funding granted to carry out this study.

References

1. Quetglas J, Rubio V. Fracturas del tercio superior de la cara. En: Quetglas J, editor. *Traumatología facial*. 4ª ed. Madrid: Sociedad Española de Cirugía Plástica; 1983. p. 92-369.
2. Haverback JF, Arenas JP, Palm CL. *Patología traumática. Primera sección: Fracturas*. En: Arenas JP, editor. *Manual de ortopedia y traumatología*. Chile: Escuela de Medicina de la Pontificia Universidad Católica de Chile; 2010. p. 9-55.
3. Coello A, Vivas C. Reconstrucción de cabeza y cuello. En: Coello A, editor. *Manual de cirugía plástica de la Sociedad Española de Cirugía Plástica Reparadora y Estética*. 2ª ed. Madrid: Impresión Médica; 2000. p. 90-136.
4. Manson PN. Traumatismos de la cara. En: Mc Carthy JG, editor. *Cirugía plástica: La cara*. Madrid: Panamericana; 1992. p. 1-268.
5. Manson P. Evaluación y manejo de las lesiones faciales. En: Weinzwieg J, editor. *Secretos de la cirugía plástica, reconstructiva y estética*. México: McGraw-Hill Interamericana; 2001. p. 146-51.
6. Carroll CM, Carroll SM, Schuschke DA, et al. Augmentation of skeletal muscle flap survival using platelet derived growth factor. *Plast Reconstr Surg*. 1998;102:407-15.
7. Rumalla VK, Borah GL. Cytokines, growth factors, and plastic surgery. *Plast Reconstr Surg*. 2001;108:719-33.
8. Lieberman JR, Daluiski A, Einhorn TA. The role of growth factors in the repair of bone. *Biology and clinical applications*. *J Bone Joint Surg Am*. 2002;84:1032-44.
9. Oyama T, Nishimoto S, Tsugawa T, et al. Efficacy of platelet-rich plasma in alveolar bone grafting. *J Oral Maxillofac Surg*. 2004;62:555-8.
10. Brägger U, Bürgin W, Fourmoussis I, et al. Computer-assisted densitometric image analysis of digital subtraction images: In vivo error of the method and effect of thresholding. *J Periodontol*. 1998;69:967-74.
11. Brägger U, Pasqualli L, Ryllander H, et al. Computer-assisted densitometric image analysis in periodontal radiography. *J Clin Periodontol*. 1988;15:27-37.
12. Kodak Dental Imaging Software Windows Version. Scientific Imaging Systems. V. 3.5.4.
13. Bennett NT, Schultz GS. Growth factors and wound healing: Biochemical properties of growth factors and their receptors. *Am J Surg*. 1993;165:728-37.
14. Anitua E. The use of plasma-rich growth factor (PRGF) in oral surgery. *Pract Proced Aesthet Dent*. 2001;13:487-93.
15. Anitua E. La utilización de los factores de crecimiento plasmáticos en cirugía oral, maxilofacial y periodoncia. *Rev RCOE*. 2003;6:305-15.
16. Eppley BL, Woodell JE, Higgins J. Platelet quantification and growth factor analysis from platelet rich plasma: Implications for wound healing. *Plast Reconstr Surg*. 2004;114:1502-8.
17. Instituto Nacional de Estadística y Geografía (INEGI). Principales causas de mortalidad por residencia habitual, grupos de edad y sexo del fallecido. México; 2013. 1 página. (Consultado en marzo de 2016). Disponible en: <http://www.inegi.org.mx/est/contenidos/proyectos/registros/vitales/mortalidad/tabulados/PC.asp?t=14&c=11817>.
18. Liceaga Reyes R, Montoya Perez LA, Segovia Hernandez S. Incidencia de fracturas maxilofaciales en pacientes del servicio de cirugía maxilofacial del Hospital Juárez de México en los años 2007-2008. *Rev Odontol Latinoamericana*. 2010;1:1-3.
19. Pacheco Ramírez MA, Rodríguez Perales MA. Fracturas mandibulares: estudio de 5 años en el Hospital Militar de México. *An ORL Mex*. 2007;4:150-3.
20. Anitua E, Sánchez M, Nurden AT, et al. New insights into and novel applications for platelet-rich fibrin therapies. *Trends Biotechnol*. 2006;24:227-34.
21. Chiang CC, Su CY, Huang CK, et al. Early experience and results of bone grafts enriched with autologous platelet gel for recalcitrant non-unions of lower extremity. *J Trauma*. 2006;63:655-61.
22. Marx RE. Platelet rich plasma: Evidence to support its use. *J Oral Maxillofac Surg*. 2004;62:489-96.
23. Freymiller EG, Aghaloo TL. Platelet-rich plasma: Ready or not? *J Oral Maxillofac Surg*. 2004;62:484-8.
24. Marx RE, Carlson ER, Eichstaedt RM, et al. Platelet-rich plasma: Growth factor enhancement for bone grafts. *Oral Surg Oral Med Oral Pathol Oral Radiol Endod*. 1998;85:638-46.
25. Eppley BL, Pietrzak WS, Blanton M. Platelet rich plasma: A review of biology and applications in plastic surgery. *Plast Reconstr Surg*. 2006;118:147-59.
26. Martínez Zapata MJ, Martí Caravajal AJ, Solá I, et al. Autologous platelet rich plasma for treating chronic wounds. *Cochrane Database Syst Rev*. 2016;(5):CD006899.
27. Moraes VY, Lenza M, Tmaoki MJ, et al. Platelet rich therapies for musculoskeletal soft tissue injuries. *Cochrane Database Syst Rev*. 2014;(4):CD010071.
28. Gruber R, Varga F, Fischer MB, et al. Platelets stimulate proliferation of bone cells: Involvement of platelet-derived growth factor, microparticles and membranes. *Clin Oral Implants Res*. 2002;13:529-35.
29. Intini G. The use of platelet rich plasma in bone reconstruction therapy. *Biomaterials*. 2009;28:56-66.
30. Arora NS, Ramanayake T, Ren YF, et al. Platelet rich plasma. A literature review. *Implant Dent*. 2009;4:303-10.
31. Anitua E, Andía I. Un nuevo enfoque en la regeneración ósea. *Vitoria, España: Puesta al día publicaciones*; 2000.
32. Weibrich G, Gnoth SH, Otto M, et al. Growth stimulation of human osteoblast-like cell. *Mund Kiefer Gesichtschir*. 2002;6:168-74.
33. Wiley J. Effect of autologous platelet-rich plasma on bone regeneration in mandibular fractures. *Den Trauma*. 2012;29:339-422.
34. Pocater A, Caruso S, Bernardi S, et al. Effectiveness of platelet-rich plasma as an adjunctive material to bone graft: A systematic review and meta-analysis of randomized controlled clinical trials. *Int J Oral Maxillofac Surg*. 2016;27:55-70.
35. Anitua E, Prado R, Troya M, et al. Implementation of a more physiological plasma rich in growth factor (PRGF) protocol. *Platelets*. 2016;4:1-8.