

Thrombophilia in Mexico

Benjamín Moncada¹, Guillermo Ruiz-Argüelles² and Olga Johnson-Ponce¹

¹Universidad Autónoma de San Luis Potosí; Hospital Central Dr. Ignacio Morones Prieto; San Luis Potosí, S.L.P., Mexico; ²Centro de Hematología y Medicina Interna de Puebla, Pue Mexico

Primary thrombophilia is among the genetic anomalies that translate into important disease. In this pathology, coagulation takes place when in reality it is not necessary. Thrombophilia is the opposite of hemophilia, where patients suffer excessive bleeding even with negligible injuries, which does not occur in normal subjects with intact coagulation mechanisms. The explanation of hemophilia is reduced to a handful of situations, whereas in the case of thrombophilia, there would be over a dozen explanations. Knowledge of these two diseases, both by the public and the medical class, is contrastingly in favor of hemophilia. In the case of this disease, there are even therapeutic means available to avoid excessive and even mortal bleeding when there is the presumption of a problem such as major surgery would be or one of minor importance such as dental extraction. At the state Ministry of Health, there are hemophilia cases registered which are provided support, while there is not a section for thrombophilia.

Dr. J. Guillermo Ruiz Argüelles has been dedicated to the search for alterations that are the cause of thrombophilia and thus is the profile of this problem in our country known. Since 17 years ago, we have been investigating the class of alteration in a patient with primary thrombophilia has, with the support of Clínica Ruiz, Laboratorios, in the city of Puebla, in charge of aforementioned Dr. Ruiz-Argüelles (Table 1).

Indication for search occurs in the presence any of the following circumstances:

- Thrombosis in a young individual, around 40 years of age.

- Thrombosis at rare sites, not usual for thromboses.
- Women that have suffered one or more miscarriages.
- Thrombosis in spite of being on anticoagulants.
- Family history of thrombosis.
- Recurrent thrombosis with no apparent precipitating factor.

As it can be appreciated in table 2, the explanation of thrombophilia is not a single one, but thrombotic phenomena can be of different origins. It is also appreciated that the vast majority of patients have more than one alteration on these laboratory tests. The average age of patients in this group was 30 years. Standing out in the lead is the presence of the methylenetetrahydrofolate reductase gene 677C-T mutation and platelet adhesiveness alteration, which constitutes the sticky platelet syndrome (SPS). To a lesser proportion, there is an increase in the plasminogen-activator inhibitor, prothrombin gene 20210G-A mutation, anti-phospholipid antibodies, and activated protein C resistance (Table 3).

Apparently, the thrombotic obstruction site is randomly established, since there is no preference for certain place in association with the detected anomaly. It is possible for this concept to be able to be clarified in the future, maybe by the activity of cell receptors or by a microenvironment of molecules such as cytokines and other affine elements that play a role in determining the obstruction site. In thrombophilia, all blood vessels can be affected: arteries and veins, as well as arterioles.

As it can be observed, there is not a single male in our series, which surely is due to the fact that, in the

Correspondence:

Benjamín Moncada
Av. Venustiano Carranza, 2395
C.P. 78290 San Luis Potosí, S.L.P., México
E-mail: moncadab@uaslp.mx

Date of reception: 23-03-2016
Date of acceptance: 19-04-2016
DOI: 10.24875/GMM.M1700029

Gac Med Mex. 2017;153:453-458
Contents available at PubMed
www.gacetamedicademexico.com

Table 1. Elements that constitute the thrombophilia profile in this series

Lipoprotein
Homocysteine
Functional fibrinogen
Fibrin aggregation
Plasminogen
Plasminogen-activator inhibitor
Platelet adhesiveness
Antithrombin III
Circulating anticoagulants
Anti-phospholipid antibodies
Anticardiolipin IgG and IgM
Anti-beta-2 glycoprotein antibodies
Coagulation protein S
Coagulation protein C
Activated protein C resistance
Mutations:
Prothrombin 20210 G-A
Methylenetetrahydrofolate reductase 677 C-T
Factor V Leiden, Liverpool, Hong Kong, Cambridge
Factor V R2 haplotype

presence of a background anomaly, there are contributing factors, and one of them, the most important, appears to be estrogenic hormones.

Publications in different places of the world have considered the MTHFR 677 mutation to be the cause of thrombotic disease¹. Although on top of the list of alterations in patients with thrombosis (62% in this series and 67% in the one of Dr. Ruiz Argüelles), in our setting, it has been regarded as a “weak” factor for that purpose and to almost always be accompanied by other alterations². In our series, only in one of 27 studied patients was the MTHFR 667 mutation the only found alteration. Interestingly, in studies with healthy subjects of the mestizo population in this country, the percentage of the presence of the 677 mutation reaches the figure of 78%².

From that point of view, it is then perceived that the most common and important alteration would be SPS. The finding of this alteration was made by Mammen in 1988, and one decade later, he wrote down his clinical findings with regard to the laboratory alteration³, thus being established that thrombosis can

occur anywhere in the body economy. There are no laboratory marker bases on which the diagnosis of the syndrome can be established, although attempts have been made to get there⁴. For the moment, it is a “functional” test where platelets are confronted at decreasing doses of epinephrine, as well as adenosine diphosphate, and are compared with normal standards⁵; since the test has to be performed immediately after the blood sample is obtained, this represents an inconvenience for a seriously ill patient when there is not an appropriate laboratory at reach. In daily practice, this test is performed once the patient has recovered from the acute problem, as in the case of thromboses at critical territories such as the brain or lung. Since SPS is common and potentially serious due to the sites that can be affected, it is important to create awareness about it⁶ and to delve into its pathogenesis⁵, as well as into therapeutic aspects^{7,8}.

The plasminogen-activator inhibitor defect occupies an intermediate place in this series, and it is already recognized to be a cause of thrombophilia in different reports⁹. One of our cases (case 13) combines this alteration with SPS¹⁰.

In routine clinical practice, a person with thrombosis with no apparent explanation is very often regarded as having antiphospholipid antibodies syndrome without considering other possibilities. Of course, this does not redound to patient benefit as regard to treatment and recovery. In our cases, the presence of antiphospholipid antibodies occupies a very low place.

When contemplating the possibility of thrombophilia, it is also usual in our setting to consider a mutation of coagulation factor V as a causative factor. Although this is possible, this alteration is rarely seen among us, and the same occurs with other factor V mutations (Cambridge, Hong Kong, and Liverpool)¹¹; however, in other countries, especially in Europe, the presence of factor V mutations is, indeed, prevalent.

In cases of thrombophilia, it is also common in our setting ordering as a priority or exclusively a determination of coagulation proteins C and S values, especially of the former. Again, this alteration is low-profile among us. In the rare cases, it occurs, there is usually a large variety of manifestations¹².

All this has great importance from different angles:

- Recognizing that there is the technical possibility to characterize the problem originated by a state of primary thrombophilia, thanks to Dr. Argüelles working group efforts.

Table 2. List with obtained results and clinical diagnoses that motivated the investigation

No.	Gender	Age (years)	Diagnosis	Affected site	Findings
1	F	28	Transient cerebral vascular insufficiency Malignant atrophic papulosis (Degos disease)	Brain Skin	Methylenetetrahydrofolate reductase 677 C-T mutation Prothrombin 20210 G-A mutation Activated protein C resistance
2	M	NB	Healthy Patient 1 son		Methylenetetrahydrofolate reductase 677 C-T mutation Prothrombin 20210 G-A mutation
3	F	38	Livedo reticularis Transient vascular insufficiency	Skin Brain	Methylenetetrahydrofolate reductase 677 C-T mutation SPS
4	F	22	Normal pregnancy Patient 3 niece		SPS
5	F	24	Middle cerebral thrombosis	Brain	Methylenetetrahydrofolate reductase 677 C-T mutation SPS
6	F	40	Mesenteric thrombosis PTE Miscarriages	Intestine and lung Placenta Legs	SPS
7	F	31	Deep venous thrombosis	Leg	SPS
8	F	30	PTE Transient cerebral vascular insufficiency	Leg Lung Brain	Methylenetetrahydrofolate reductase 677 C-T mutation SPS Prothrombin 20210 G-A mutation PAI
9	F	17	Normal delivery Patient 8 daughter	Placenta	SPS Prothrombin 20210 G-A mutation
10	F	17	Erythema nodosum Pre-term delivery	Skin and placenta	SPS Prothrombin 20210 G-A mutation PAI
11	F	34	Longitudinal sinus occlusion	Brain	SPS
12	F	48	White atrophy	Skin Lung	Methylenetetrahydrofolate reductase 677 C-T mutation Prothrombin 20210 G-A mutation
13	F	12	White atrophy Livedoid vasculopathy	Skin	SPS PAI
14	F	43	Skin White atrophy Previous venous thromboses	Skin Leg veins	SPS Antiphospholipid antibodies Anti-beta-2 glycoprotein
15	F	37	Post-abortion PTE	Leg veins Lung	SPS PAI
16	F	40	Sneddon syndrome	Skin and brain	Antithrombin (1%) Protein C (8) Leiden (6) Homocystein (1%)
17	F	33	Pre-term delivery Grandmother and mother with pre-eclampsia	Placenta	SPS PAI
18	F	13	Thrombophlebitis	Leg veins	SPS Circulating anticoagulants Anti-beta-2 glycoprotein antibodies Anticardiolipin antibodies Methylenetetrahydrofolate reductase 677 C-T mutation
19	F	40	Cerebelous artery thrombosis	Brain	PAI Methylenetetrahydrofolate reductase 677 C-T mutation Elevated fibrinogen

(Continue)

Table 2. List with obtained results and clinical diagnoses that motivated the investigation (Continued)

No.	Gender	Age (years)	Diagnosis	Affected site	Findings
20	F	38	Transient vascular insufficiency	Brain	PAI
21	F	40	White atrophy	Skin	Methylenetetrahydrofolate reductase 677 C-T mutation Prothrombin 20210 G-A mutation
22	F	26	Longitudinal sinus thrombosis	Brain	PAI Methylenetetrahydrofolate reductase 677 C-T mutation DM Hypertriglyceridemia
23	F	40	PTE	Lung Leg veins	Methylenetetrahydrofolate reductase 677 C-T mutation
24	F	21	Anetoderma	Skin	SPS Methylenetetrahydrofolate reductase 677 C-T mutation
25	F	34	Middle cerebral thrombosis	Brain	SPS Methylenetetrahydrofolate reductase 677 C-T mutation Antiphospholipid antibodies
26	F	41	White atrophy Progressive scapula-humeral muscle dystrophy	Skin	Methylenetetrahydrofolate reductase 677 C-T mutation Elevated fibrinogen and fibrin aggregation
27	F	23	Abortions Pre-term deliveries Eclampsia Thrombosis legs	Placenta Leg veins	Antiphospholipid antibodies Anti-beta-2 glycoprotein antibodies Methylenetetrahydrofolate reductase 677 C-T mutation

DM: diabetes mellitus; F: female; M: male; PAI: plasminogen-activator inhibitor; PTE: pulmonary thromboembolism; SPS: sticky platelet syndrome.

Table 3. Obtained results

Methylenetetrahydrofolate reductase 667 C-T gene mutation	17
Platelet activity increase	16
Plasminogen-activator inhibitor increase	8
Prothrombin 20210 G-A gene mutation	7
Antiphospholipid antibodies	3
Activated fibrinogen increase	1
Fibrin aggregation increase	1

- Establishing the regional nature of these alterations, and this way not following research models operating in other countries, but to preferably look for anomalies occurring among us.
- Appreciating the role of estrogens in this disease. Case 13 example illustrates this point: a healthy patient for her entire childhood who at 12 years of age had arteriolar occlusion, which resulted in white atrophy/livedoid vasculopathy syndrome just when adolescence began (Fig. 1). Furthermore, women in whom thrombosis occurs during pregnancy (cases 15, 17 and 27).
- Creation of preventive criteria to try to prevent thrombosis recurrence in affected people and to

prevent for this to occur in close relatives by looking in them for the specific anomalies of the sick family member. This is illustrated by cases 4 and 17. In the first one, when patient 3 healthy niece got pregnant, she was detected to share SPS with her aunt, and therefore, she had a monitored pregnancy that ended successfully. Something similar happened with case 17, which due to pathology suggestive of thrombotic pathogenesis detected in her mother and grandmother in the remote past, she had the thrombophilia profile determined, where SPS and increased plasminogen-activator inhibitor levels were found, and therefore, she also received special care, with her pregnancy being terminated at 36 weeks, as placental thrombosis was found to be starting to develop (Fig. 2).

As with any new knowledge in some practices, particularly in medical practice, there is often ignorance, non-acceptance, or rejection of it, which would hinder proper patient care. This is evident in cases 14 and 16. In the first one, a patient with white atrophy and previous venous thrombosis had a sister older than 40 years an a first pregnancy; the person in charge of her gynecologic care was advised to carry out the tests that, in her sister, were positive in

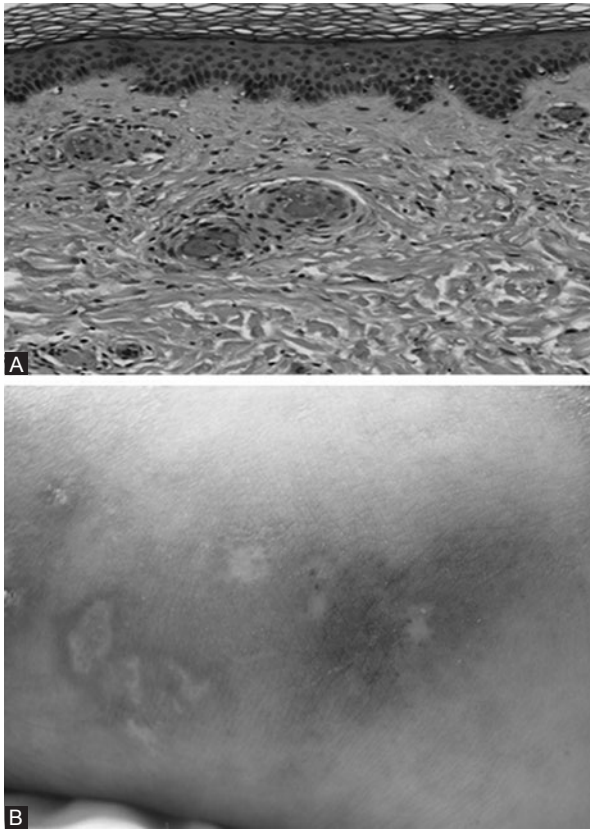


Figure 1. (A) Patient 13 biopsy with foot vessels arteriolar occlusion without inflammation. (B) Active and healed skin lesions.

order for special care to be provided in the course of her pregnancy. This recommendation was not taken into account and unnecessary risks were run. In case 16, with Sneddon syndrome, which consists in leg and also brain arteries occlusion, the recommendation to perform the thrombophilia profile was accepted, but it only was done partially; four tests, two of them occupying <1% in Mexican experience and other two that are at 8th and 6th places in our country. The reason: she only agreed to undergo the tests that were performed at the health institution she belonged to.

The treatment of thrombophilia acute episodes will depend on the affected site and the specialists' intervention required by the affected region. However, only according to the alteration in question will there be temporary or indefinite need for one or another drug, as well as for general measures and common sense, such as avoiding immobility, for example, in long trips, as well as avoiding dehydration and unnecessary medication or "natural products" that might be adjuvant in the thrombotic process.

Stress has only recently been known to influence on thrombosis¹³, and counseling the patients in this sense would, therefore, be highly recommendable.

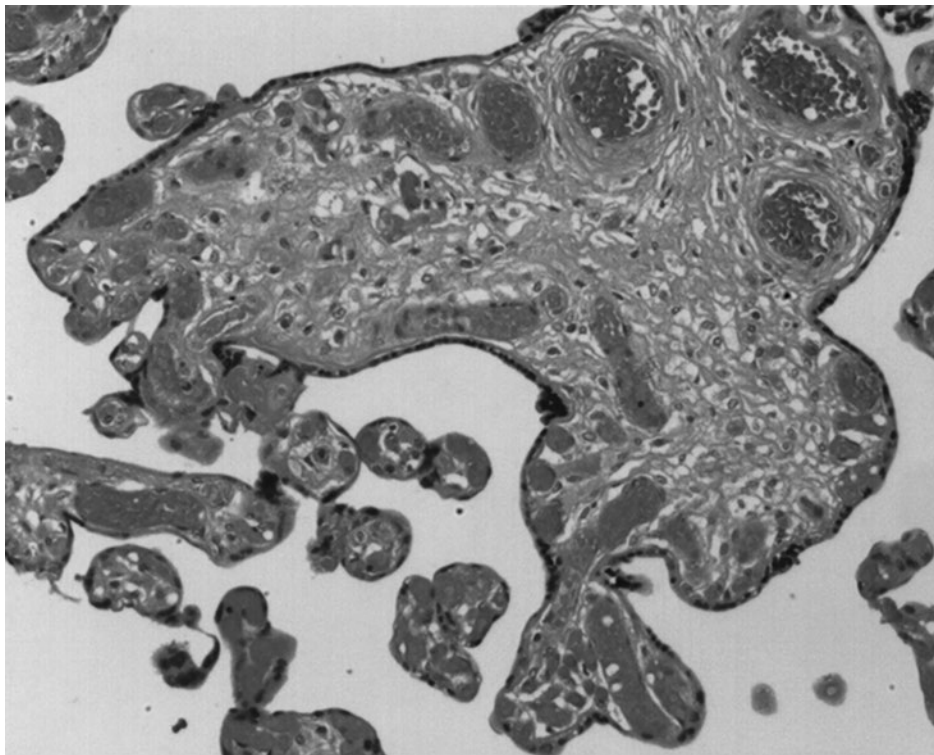


Figure 2. Case 17 placenta. She was a 33-year-old patient who had her pregnancy interrupted at 36 weeks due to the presence of fetal distress. Placental vessels thromboses starting to develop are appreciated in the photograph.

References

1. Ali Z, Troncoso JC, Fowler DR. Recurrent cerebral venous thrombosis associated with heterozygote methylenetetrahydrofolate reductase C677T mutation and sickle cell trait without homocysteinemia. An autopsy case report and review of literature. *Forensic Sci Int.* 2014;242:e52-5.
2. Ruiz-Delgado G, Ruiz Argüelles GJ. Estudios en México sobre el gen MTHFR. *Salud Pública de México.* 2008;50:5.
3. Mammen EF. Sticky platelet syndrome. *Semin Thromb Hemostat.* 1999;25:361-5.
4. Ruiz Argüelles GJ, Garces Eisele J, Camacho-Alarcón C, et al. Primary thrombophilia in Mexico IX. Primary thrombophilia in Mexico IX: the glycoprotein IIIa PLA1/A2 polymorphism is not associated with the sticky platelet syndrome phenotype. *Clin Appl Thromb Hemost.* 2013; 19:689-92.
5. Ruiz-Argüelles GJ, López-Martínez B, Cruz-Cruz D, et al. Primary thrombophilia in Mexico III. A prospective study of the sticky platelet syndrome. *Clin Appl Thromb Hemost.* 2002;8:T1-T5.
6. Moncada B, Ruiz-Argüelles GJ, Castillo-Martínez C. The sticky platelet syndrome. *Hematology.* 2013;18:230-2.
7. Velázquez-Sánchez-de Cima S, Zamora-Ortiz G, Hernández-Reyes J, et al. Primary thrombophilia in Mexico X. A prospective study of the treatment of the sticky platelet syndrome. *Clinical and Applied Thrombosis/hemostasis.* 2015;21:91-5.
8. Kubisz P, Stasko J, Holly P. Sticky platelet syndrome. *Semin Thromb Hemost.* 2013;39:674-83.
9. Agirbasli M, Eren M, Eren F, et al. Enhanced functional stability of plasminogen activator inhibitor-1 in patients with livedoid vasculopathy. *J Thromb Thrombolysis.* 2011;32:59-63.
10. Castillo-Martínez C, Moncada B, Valdés-Rodríguez R, et al. Livedoid vasculopathy (LV) associated with sticky platelets syndrome type 3 and enhanced activity of plasminogen activator inhibitor (PAI-1) anomalies. *Int J Dermatol.* 2014;53:1495-7.
11. Ruiz-Argüelles GJ, Poblete Naredo I, Reyes Nuñez V, et al. Primary thrombophilia in Mexico IV. Frequency of the Leiden, Cambridge, Hong Kong, Liverpool and HR2 haplotype polymorphisms in the factor V gene of a group of thrombophilic Mexican Mestizo patients. *Rev Invest Clin.* 2004;56:600-4.
12. De Lemus Varela ML, Arriaga-Dávila J de J, Salinas-Lopez MP. Protein C congenital deficiency. A case report. *Gac Med Mex.* 2005;141:229-31.
13. Surtees PG, Wainwright NW, Luben NR, et al. Psychological distress, major depressive disorders, and risk of stroke. *Neurology.* 2008;70:788-94.