

Pulmonary pseudotumor in granulomatosis with polyangiitis (GPA). Pulmonary cancer and/or GPA? Diagnostic implications of pulmonary nodules

Gabriel Horta-Baas^{1*}, Esteban Meza-Zempoaltecatl², Mario Pérez-Cristóbal² and Barile-Fabris Leonor Adriana²

¹Rheumatology Department, Hospital General Regional 220, IMSS, Toluca; ²Rheumatology Department, Hospital de Especialidades, Centro Médico Nacional Siglo XXI, IMSS, Mexico City, Mexico

Abstract

Granulomatosis with polyangiitis (GPA), formerly known as Wegener's granulomatosis, is a systemic necrotizing vasculitis, which affects small and medium sized blood vessels and is often associated with cytoplasmic anti-neutrophil cytoplasmic antibodies (ANCA). Inflammatory pseudotumor is a rare condition characterized by the appearance of a mass lesion that mimics a malignant tumor both clinically and on imaging studies, but that is thought to have an inflammatory/reactive pathogenesis. We report a patient with a GPA which was originally diagnosed as malignancy. (Gac Med Mex. 2016;152:468-74)

Corresponding author: Gabriel Horta-Baas, gabho@hotmail.com

KEY WORDS: Granulomatosis with polyangiitis. Pseudotumor. Malignancy.

Introduction

According to the 2012 revised Chapel Hill classification, granulomatosis with polyangiitis (GPA), previously known as Wegener's granulomatosis (WG), is an autoimmune systemic disease of unknown etiology, characterized by necrotizing granulomatous inflammation of the respiratory tract and vasculitis affecting medium-sized and small vessels¹. Clinical manifestations can be very heterogeneous, but it characteristically affects the upper and lower respiratory tract and the kidneys. Pulmonary involvement is one of GPA's main features, it is the initial manifestation in 45% of patients, and up to 87% develop it in the course of the disease. There is an atypical manifestation of GPA, where initial clinical data, imaging studies and histopathology report are suggestive but not diagnostic of lung cancer.

Presentation of the case

This is the case of a 39-year old male who was admitted in the hospital presenting with asthenia, general malaise, intermittent fever (3 to 4 times a month), diaphoresis with no time of day predominance and loss of 10-kg weight in 6 months. He had been diagnosed with chronic sinusitis since he was 20 years of age, treated with mometasone. At 23 years, multiple sclerosis diagnosis was contemplated due to the presence of temporal hemianopia. One year previous to his admission, he was diagnosed with chronic otitis media and severe unilateral sensorial-type hearing loss. He had no history of smoking or use of drugs.

At admission, he referred arthralgias at the level of knees, elbows, wrists and proximal interphalangeal joints. On physical examination, anterior uveitis and unilateral

Correspondence:

*Gabriel Horta-Baas
Hospital General Regional 220, IMSS
Paseo Tollocan, 620
C.P. 50150, Toluca, Edo. de México, México
E-mail: gabho@hotmail.com

Date of reception: 14-06-2015

Date of acceptance: 24-07-2015

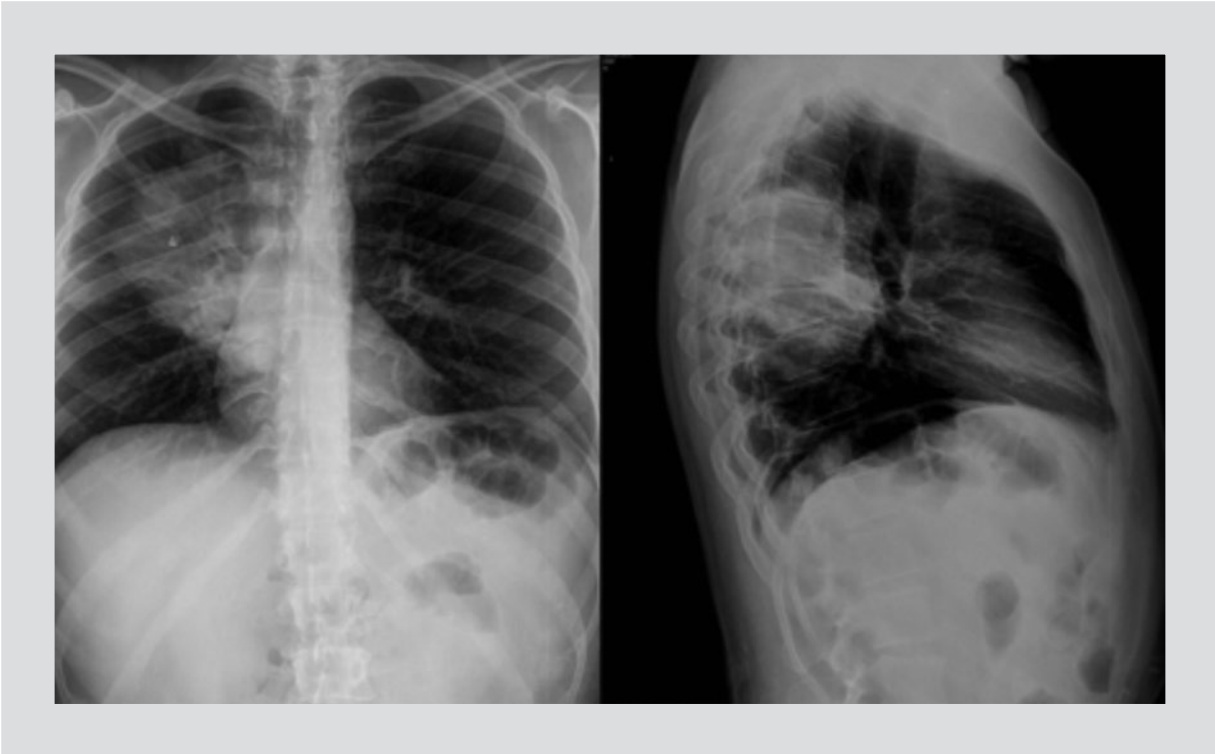


Figure 1. AP and lateral X-ray. Large, rounded parahilar opacity with well-defined margins.

scleritis, right eye visual acuity of 20/30 and right eye 20/60, nasal septum perforation, one lingual ulceration and another on the first premolar vestibular wall, bilateral hearing loss, paresthesias on the feet and cutaneous vasculitis on the legs were documented. The visual field test reported temporal hemianopia. His laboratory tests showed globular sedimentation rate and C-reactive protein elevation, proteinuria in the urinalysis, reduced creatinine clearance, positive cytoplasmic-pattern anti-neutrophil cytoplasmic antibodies (c-ANCA) and positive anti-proteinase 3 antibodies (74.7 mU/ml; negative < 5 mU/ml).

Mononeuropathy of the peroneal nerve was documented by neurophysiological study. Skin biopsy histopathology report confirmed leukocytoclastic vasculitis; sural nerve biopsy reported minimal isolated demyelination foci, blood vessels without significant microscopic changes and very scarce perineural lymphocytes.

GPA diagnosis was concluded, with 26 points on the Birmingham Vasculitis Activity Score (BVAS). The patient was treated with intravenous methylprednisolone 1 g every 24 h for 3 consecutive days, followed by prednisone 1 mg/kg/day. Induction scheme with intravenous cyclophosphamide was started according to the British Society for Rheumatology guidelines².

A large parahilar mass was appreciated on chest X-ray (Fig. 1); computed tomography (CT) showed a solid tumor of 12 cm in diameter with ill defined margins on the right lung, with mediastinal adenopathies and bilateral pulmonary nodules with malignant characteristics (Fig. 2). A pleural biopsy was obtained, with histopathology report of poorly-differentiated malignant neoplasm.

In December 2010, due to the suspicion of lung cancer, the patient was assessed by the medical oncologist, with the diagnosis of Unknown Primary Cancer, with poor-prognosis factors, ECOG 2, and a survival expectancy of 6 to 7 months being concluded. A new biopsy was practiced, with no signs of malignancy being found.

With the cyclophosphamide induction scheme, remission of systemic activity and reduction of the size of the lesion was achieved (Figs. 3 A and B), and the patient continued with prednisone 20 mg/day and azathioprine 2 mg/kg/day. At follow-up, 4 years after hospitalization, activity remission and pulmonary lesions resolution was achieved (Figs. 3 C and D), with the patient remaining on maintenance treatment with azathioprine 75 mg/day and prednisone 5 mg/day.

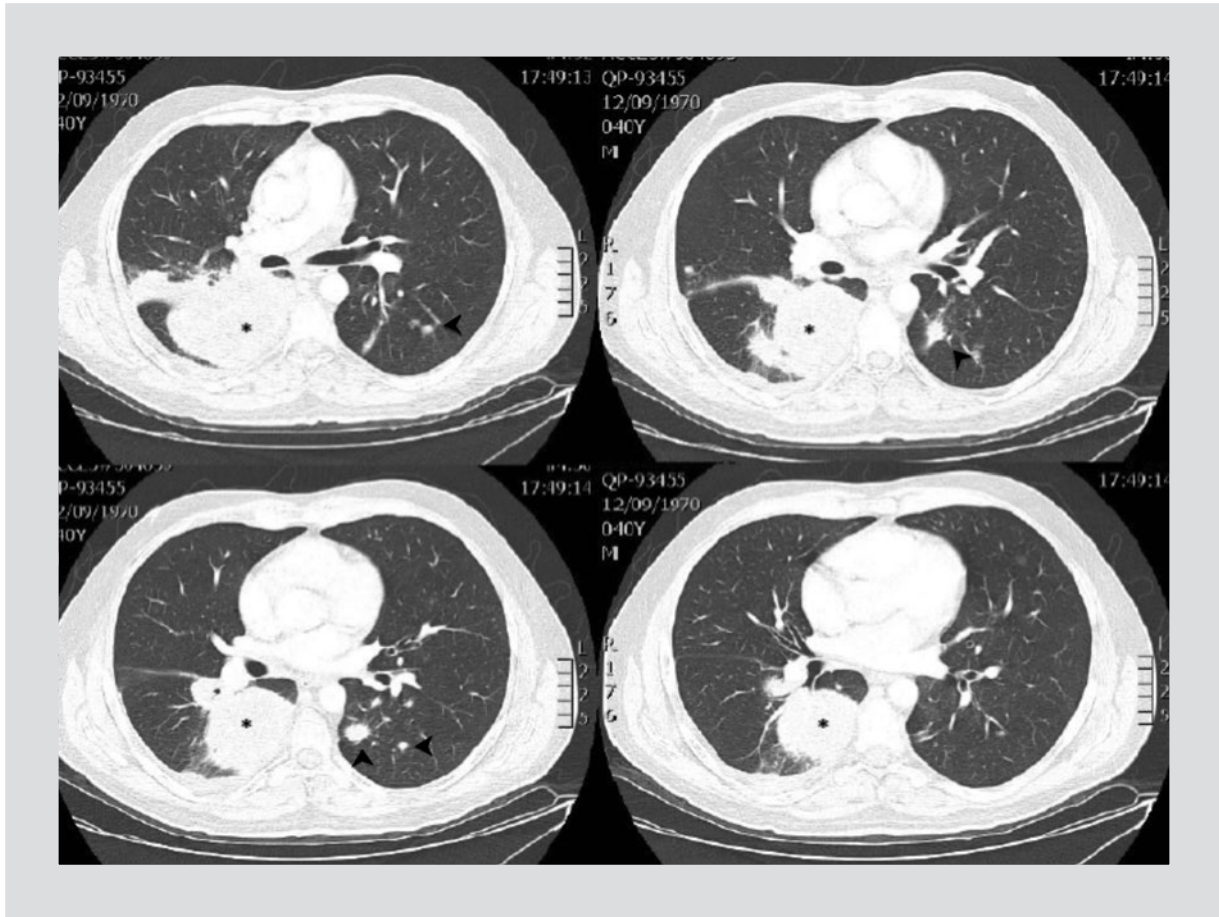


Figure 2. Pulmonary high-resolution CT. Ovoid-shaped (*), well-defined lesion with lobulated borders, located at the medial segment of right lung middle lobe, of heterogeneous density, with 120 x 82 mm diameter and attenuation values between 60 and 28 UH, same side pleural recess fluid occupation. At the level of the left pulmonary parenchyma, multiple hyperdense (arrowheads), amorphous images with spiculated borders, calcific density, are identified, the largest of 10 x 11 mm and the smallest of 5.5 mm in diameter; at lower lobe, stellate-appearing lesion, with pleural tail of 1.65 x 1.65 mm in diameter and attenuation values of 48 UH. Ovoid, hypodense right paratracheal lesions are identified with 19 x 10 mm and 17 x 10 mm dimensions in relation to adenopathies.

Discussion

Primary vasculitis are complex pathologies, with varied clinical manifestations that can be common to those occurring in multiple conditions. Pulmonary manifestations are one of the main findings in GPA, with the most common symptoms being cough, hemoptysis and pleuritis. Vasculitis that produce pulmonary granulomatous disease are characterized by the presence of ANCA-type antibodies, and produce a granulomatous inflammation of the respiratory tract with necrotizing vasculitis and renal involvement with hematuria and proteinuria³. In most cases, antibodies are directed against cytoplasmic proteinase 3. In the pathogenesis of this type of pulmonary condition, an inflammatory cell-response has been implicated, which leads to the generation of granulomas formed by an inflammatory

infiltrate composed of neutrophils, lymphocytes, plasma cells, histiocytes and eosinophils³.

Radiological manifestations of lung involvement in GPA are varied, both at initial presentation and in the course of the disease, not offering data that can be considered specific, although within the clinical context they are highly useful. Most common findings are pulmonary infiltrates and nodules. Nodules in most patients are often multiple, with well-defined margins, occurring with no zonal predilection, and normally add up to less than 20; with variable diameter, they usually measure between 2 and 4 cm, but they can measure from a few mm to 10 cm and in 50% they are accompanied by cavitation⁴. In up to 25% of cases, nodules can be isolated. Hilar and mediastinal adenopathies are rare manifestations⁵. Since pulmonary nodules are the main radiological manifestation at the pulmonary

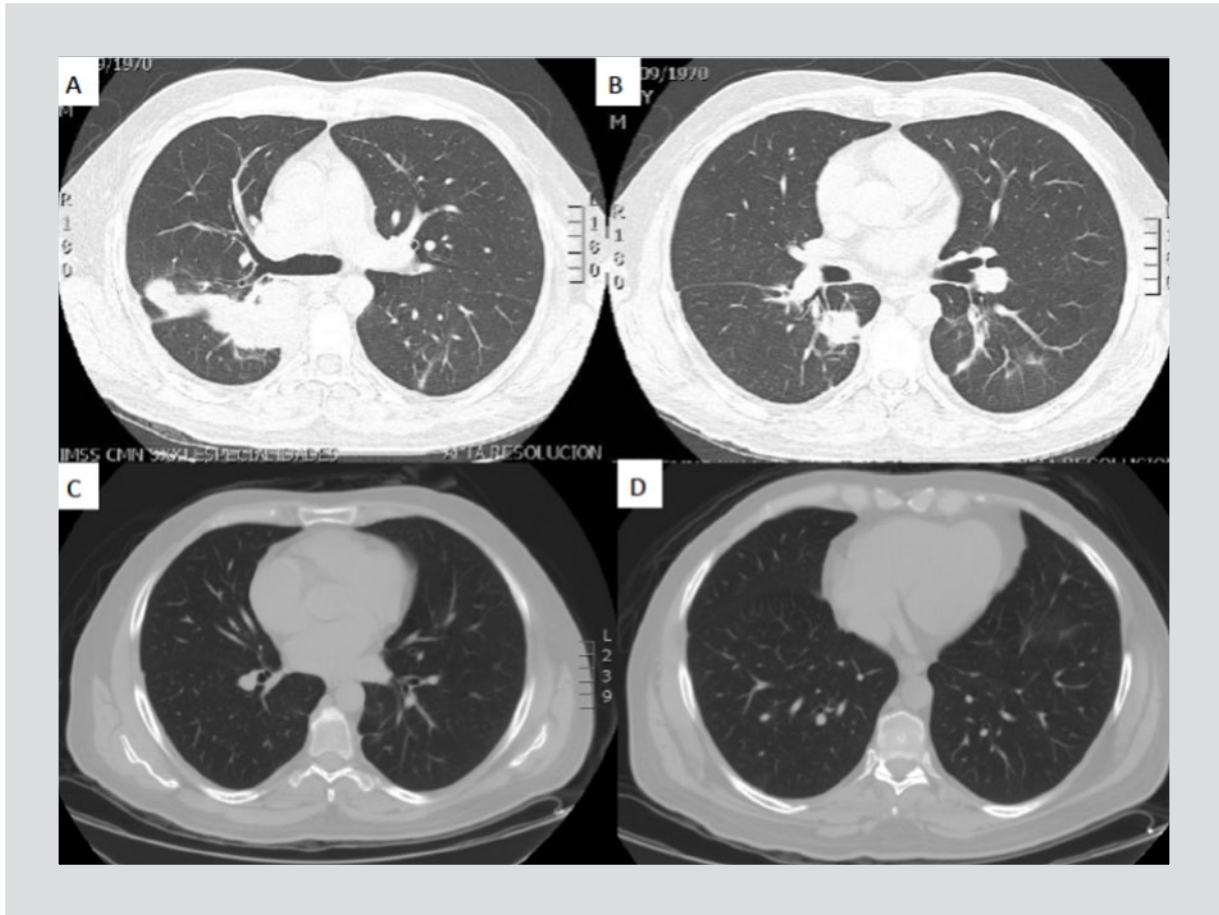


Figure 2. A and B: CT after treatment with cyclophosphamide. Decrease of consolidation area and nodules in relation with tumor lesion located at right lung lower lobe upper segment of poorly-defined spiculated borders with 52 x 44 mm diameters and attenuation values of 47 UH; **C and D:** CT-scan at 4 years of treatment with pulmonary lesions resolution.

level, the initial study is often made with more prevalent diagnoses such as: infectious processes by micobacteria and fungi, malignant tumors or metastases of solid neoplasms^{4,6}. Very large sized nodules are infrequent, and can be easily mistaken for primary or metastatic malignant tumors, especially when accompanied by adenopathies, and differential diagnosis with neoplastic processes is essential.

In our case, the initial X-ray showed a large unilateral nodular lesion, and CT documented a very large pulmonary nodule with lesions consistent with metastases, which are unusual findings in GPA and, therefore, there was no diagnostic difficulty in view of the possibility of a malignant disease. From the radiological point of view, benign nodules are considered to normally have well-defined margins and smooth contour, whereas malignant nodules have poorly-defined or spiculated margins and irregular or lobular contour⁷, as in our case. However, there is considerable overlapping between benign and malignant

nodules with regard to borders and contour. The spiculated image with adjacent bronchovascular bundles distortion is highly suggestive of malignant tumors, with a predictive value of 90%; however, nodules due to infection or inflammation may also show this appearance⁷.

Inflammatory pseudotumor association is described in a wide spectrum of rheumatologic and autoimmune diseases, including GPA (Table 1). Blennerhassett et al.⁸ reported 4 cases with limited WG variety where pulmonary resection was performed due to suspected cancer. In the thoracotomy procedure, extensive fibrosis and the relatively poorly defined margins of the lesion also suggested an infiltrating neoplasm⁸. Fouad-Rabahi et al.⁹ reported the case of a pseudotumor in WG in a 61-year old male smoker who had respiratory symptoms and chest X-ray showed a nodular opacity at the right hemithorax lower third, chest CT-scan revealed a 4.2 cm x 3.1 cm lesion, contiguous to the parietal pleura and positive c-ANCA.

Table 1. Characteristics of patients with pulmonary pseudotumor due to granulomatosis with polyangiitis

Age (years)/ Gender/ Reference	Findings on imaging studies	Findings on histopathological study	Clinical manifestations	Treatment employed	Outcome
50/Female ⁸	Basal bilateral radiographic opacities. On TC, 1 more solid opacity at pulmonary base, 3 small rounded intrapulmonary lesions. No evidence of calcification or cavitation.	Sputum cytology showed atypical cells, but no neoplastic cells. Necrosis and extensive infiltration by lymphocytes and plasma cells, large numbers of multinucleated giant cells and giant cell-granulomatous vasculitis were found in pulmonary tissue.	Cough and chest pain.	Anti-TB drugs Lobectomy	Not reported
64/Male ⁸	Opacity at upper left lobe apical segment.	Atypical cells reported on sputum cytology. No malignant cells were observed on bronchial aspirate. Same findings of previous case. Giant cells were found in lymph nodes, but without vasculitis.	Productive cough, weight loss, anorexia.	Pneumonectomy	Symptom resolution
68/Female ⁸	Left upper lobe poorly defined opacity	Granulomatous vasculitis without extended necrosis. Perivascular and peribronchial infiltration with lymphocytes and plasma cells.	Weight loss	Lobectomy	At 6 months, symptomatic relapse treated with prednisone and cyclophosphamide with improvement.
64/Male ⁸	CT showed solid lesion at the right lung lower portion axillary segment, and the rest of the lobe with honeycomb appearance due to cavities. Hilar lymphadenopathy	Mucosal biopsies showed normal bronchial mucosa. Loss of lung architecture due to a granulomatous process where many multinucleated cells were observed. Small areas of necrosis were observed. Presence of pulmonary vasculitis characterized by chronic inflammatory cells, predominantly lymphocytes.	Weakness, weight loss, chest pain.	Pneumonectomy	Symptom resolution.
71/Female ¹⁵	Multiple pulmonary nodules, absence of lymphadenopathy	Sputum cytology showed a three-dimensional cluster of cells with intra-cytoplasmic vacuoles, increased nucleus-to-cytoplasm, and prominent nucleoli, suggestive of adenocarcinoma.	Productive cough, hemoptysis, general malaise, anorexia and weight loss.	Prednisone Cyclophosphamide	Pulmonary lesions resolution.
70/Female ¹¹	CT showed 3 pulmonary nodules with irregular margins.	Lung biopsy: presence of foamy histiocytes, epithelioid cells, and some groups of cells with higher nucleus/plasma ratio. Prominent nucleoli were identified, which were suggestive of adenocarcinoma diagnosis, were identified.	Productive cough, chest pain, saddle nose.	Prednisolone Cyclophosphamide	Good treatment response.

continue

Table 1. Characteristics of patients with pulmonary pseudotumor due to granulomatosis with polyangiitis (continued)

Age (years)/ Gender/ Reference	Findings on imaging studies	Findings on histopathological study	Clinical manifestations	Treatment employed	Outcome
52/Male ¹¹	X-ray showed apical and left upper lobe irregular lesions. Absence of hilar lymphadenopathy.	Sputum cytology showed atypical cells, suspicious of bronchogenic carcinoma.	Cough, chest pain, weight loss, nocturnal diaphoresis, nasal mucosa ulcerations, cutaneous vasculitis and glomerulonephritis.	Prednisolone Cyclophosphamide	Pulmonary lesions resolution.
52/Male ¹⁰	X-ray with parahilar infiltrates, right pleural effusion. CT revealed bilateral pulmonary nodules, the largest with central cavitation	Renal biopsy showed fibrous crescents, diffuse glomerulosclerosis and extended interstitial fibrosis.	Dry cough, dyspnea, fever and glomerulonephritis.	Prednisone Cyclophosphamide	At 6 months, cavitated lesion resolution. Persistence of some small pulmonary nodules.
45/Male ⁶	Multiple nodules and masses on both lungs, with some of them displaying cavitation.	Fine needle aspiration biopsy with cellular detritus, consistent with tumor necrosis. Bronchial biopsies demonstrated extended necrosis and vasculitis, with no features of neoplastic nature.	Dry cough, dyspnea, anorexia, weight loss, oral ulcerations and cutaneous vasculitis.	Methylprednisolone Cyclophosphamide	Had a period of improvement. Subsequently, died of pneumonia complicated by acute renal failure.
61/Male ⁹	X-ray showed a nodular opacity at the right hemithorax lower third. CT revealed right hemithorax extended lesion, contiguous to the parietal pleura.	Aspiration biopsy: areas of fibrosis and areas of extensive necrosis associated with an inflammatory process.	Cough, dyspnea, fever, labyrinthitis, hypoacusis.	Not reported	Pulmonary lesions resolution.

As in our case, there are 3 reported cases where GPA was initially considered to be a metastatic lung adenocarcinoma^{10,11}. In the described cases, localized symptoms were found at the pulmonary level with imaging studies suggestive of malignant pulmonary lesions and, therefore, WG diagnosis was not considered.

Campaignha et al.⁶ describe the case of a 45-year old male smoker initially diagnosed with stage IV non-small cell lung cancer, owing to the fine needle aspiration cytology result. The patient underwent chemotherapy cycles with carboplatin and gemcitabine and achieved a complete remission after 3 cycles, which led to diagnostic reassessment; c-ANCA and anti-proteinase were determined to be positive, with WG limited variety diagnosis being concluded. Diagnostic confusion was attributed to the fact that the patient had only

pulmonary involvement and the lesions were suggestive of metastatic disease and ANCA values were not initially determined⁶.

ANCA have shown to be highly useful, they constitute a sensitive and specific biomarker and they test positive in between 40 and 95% of GPA patients. However, they are not pathognomonic and can appear in other conditions, including different forms of cancer; in these patients, most cases occur with an atypical ANCA pattern, not associated with any specific antigen (proteinase 3 or myeloperoxidase)¹². Small et al.¹³ reported the case of a primary T cell lung lymphoma, which was initially diagnosed as WG owing to a right parahilar mass, positive c-ANCA and bronchial mucosa biopsy with lymphoid lymphocytic infiltrate and perivascular mononuclear cells with necrosis areas suggestive, but not diagnostic of WG.

Sputum and fine needle aspiration cytology results can be problematic and mix up pathologists, since they can be misdiagnosed as cancer. On histopathology analyses, acute inflammation, necrotic detritus, multinucleated giant cells, reactive epithelial cells and histiocytes, and atypical bronchial cells, often present in GPA, can be misinterpreted as adenocarcinoma or even as squamous cell cancer^{6,11,14}. Although multinucleated giant cells and epithelioid histiocytes are considered relatively more specific in the cytology analysis, acute inflammation and necrosis are the most common histopathological findings in GPA¹⁵. Two cases of WG with initial diagnosis of adenocarcinoma based on sputum cytology results have been described^{11,15}, as well two cases based on fine needle aspiration biopsy cytology results^{11,14}. In the described cases, cytological characteristics were suggestive, but not diagnostic, of adenocarcinoma. WG histological diagnosis requires for necrotizing vasculitis with predominant involvement of medium caliber arteries, and necrotizing granulomatous inflammation with geographic necrosis to be identified^{6,15}.

On the other hand, adding to diagnostic complexity, there are cases reported with an initial diagnosis of GPA that concluded in lung cancer and cases with presence of GPA and lung adenocarcinoma¹⁶. Rimoldi et al.¹² reported the case of a 69-year old woman presenting with fatigue, anorexia, weight loss, arthralgias, peripheral neuropathy, acute renal failure, acute phase reactants elevation, positive perinuclear-pattern ANCA and positive anti-myeloperoxidase antibodies, chest and abdomen X-ray without abnormalities; with a diagnosis of ANCA-associated vasculitis, the patient received treatment with plasmapheresis and died at 14 days owing to hemorrhagic complications. In the autopsy examination, lung adenocarcinoma was demonstrated with no data of vasculitis¹².

Based on the above, the GPA relationship with cancer can be classified in 3 groups: Malignant tumors mimicking vasculitis; vasculitis mimicking malignant tumors and coexistence of a malignant tumor with vasculitis. GPA can be a difficult-to-diagnose condition, since sometimes it can mimic other pathologies' symptoms, as well as overlapping them. Including it in the differential diagnosis is essential in order to establish an adequate treatment as soon as possible. Clinical

suspicion is the most important element for diagnosis, and it requires adequate interpretation of clinical, imaging, laboratory and histopathological findings.

Conclusion

GPA diagnosis is not always easy for clinicians and pathologists, and can be mistaken with neoplastic processes. ANCA are useful biomarkers as diagnostic complementation that can support the diagnosis if a high pre-test probability is met, particularly in cases with atypical presentations. ANCA determination is recommended in patients with multiple pulmonary lesions, even in the absence of other clinical signs and symptoms of GPA, in order to employ the appropriate treatment and avoid complications.

References

1. Comarmond C, Cacoub P. Granulomatosis with polyangiitis (Wegener): Clinical aspects and treatment. *Autoimmun Rev.* 2014;13:1121-5.
2. Rúa-Figueroa Fernández de Larrinoa I, Erausquin Arruabarrena C. Treatment of ANCA-associated systemic vasculitis. *Reumatol Clin.* 2010;6:161-72.
3. Martín-Suñe N, Ríos-Blanco JJ. Afectación pulmonar de las vasculitis. *Arch Bronconeumol.* 2012;48:410-8.
4. Gómez-Gómez A, Martínez-Martínez MU, Cuevas-Orta E, Bernal-Blanco JM, Cervantes-Ramírez D, Abud-Mendoza C. Manifestaciones pulmonares de la granulomatosis con poliangeitis. *Reumatol Clin.* 2014;10:288-93.
5. Lohrmann C, Uhl M, Kotter E, Burger D, Ghanem N, Langer M. Pulmonary manifestations of Wegener granulomatosis: CT findings in 57 patients and a review of the literature. *Eur J Radiol.* 2005;53:471-7.
6. Campainha S, Goncalves M, Tavares V, Casteloes P, Marinho A, Neves S. Granulomatosis with polyangiitis initially misdiagnosed as lung cancer. *Rev Port Pneumol.* 2013;19:45-8.
7. Truong MT, Sabloff BS, Ko JP. Multidetector CT of solitary pulmonary nodules. *Thorac Surg Clin.* 2010;20:9-23.
8. Blennerhassett JB, Borrie J, Lichter I, Taylor AJ. Localized pulmonary Wegener's granuloma simulating lung cancer: report of four cases. *Thorax.* 1976;31:576-84.
9. Fouad-Rabahi M, Bertti-Coelho L, de Oliveira-Borges E, Stival-Lemes M, Mendes de Castro W, de Souza-Carneiro S. Lung pseudotumor as the initial presentation of Wegener's granulomatosis. *J Bras Pneumol.* 2009;35:392-5.
10. de Oliveira RV, Zanetti G, Marchiori E. Multiple pulmonary nodules. Wegener's granulomatosis simulating pulmonary metastases. *QJM.* 2013;106:1143-4.
11. Uppal S, Saravanappa N, Davis JP, Farmer CK, Goldsmith DJ. Pulmonary Wegener's granulomatosis misdiagnosed as malignancy. *BMJ.* 2001;322:89-90.
12. Rimoldi L, Sinoco RA. Lung cancer mimicking anti-neutrophil cytoplasmic antibody associated systemic vasculitis. *J Symptoms Signs.* 2012;1:121-4.
13. Small JH, Round A, Simpson RH, Ferguson AD. Wegener's granulomatosis simulated by a T cell lymphoma of the lung. *Thorax.* 1991;46:465-6.
14. Cesario A, Meacci E, Mule A, Margaritora S. Wegener disease mimicking central lung cancer. *Eur J Cardiothorac Surg.* 2002;22:626.
15. Yu-Li L, Yung-Hsiang H. Wegener's granulomatosis simulates pulmonary adenocarcinoma. *Tzu Chi Medical Journal.* 2013;27:38-40.
16. Sastre-López A, Íñigo-Vanrell V, Gascó-Company JM. Granulomatosis de Wegener y cáncer. *Nefrología.* 2008;28:232.