

Thrombus in transit and submassive pulmonary thromboembolism successfully treated with tenecteplase

Luis Arboine-Aguirre*, Edgardo Figueroa-Calderón, Alicia Ramírez-Rivera, Bertha Gaxiola-Cadena, Anabel García-Sosa and Carolina González-Garay

UMAE, Cardiology Hospital No. 34, Monterrey, Nuevo León, N.L., Mexico

Abstract

Right heart thrombus is a slightly detectable condition. In patients presenting with acute pulmonary embolism, the finding of thrombus in transit has been associated with high in-hospital mortality. We present a case of a 50-year-old male patient with acute pulmonary embolism and a thrombus in transit in the right atrium. We took the decision to perform fibrinolysis with tenecteplase, presenting significant improvement in the clinical condition, without any complications related to the therapy. Our case demonstrates the effectiveness of thrombolytic therapy in cases of pulmonary embolism and thrombus in transit in right chambers. (Gac Med Mex. 2017;153:120-3)

Corresponding author: Luis Arboine-Aguirre, luisarboine1986@gmail.com

KEY WORDS: Echocardiography. Pulmonary embolism. Thrombolytic therapy. Thrombus in transit.

Introduction

Venous thromboembolism (VTE) is the third most common cardiovascular condition, with a yearly incidence of 100-200 cases/100,000 population. Pulmonary thromboembolism (PTE) is the most serious presentation of VTE and an important cause of morbidity, mortality and hospitalization¹.

Thrombus in transit is defined as a thrombus that is temporally lodged in the right heart chambers on its way to the pulmonary artery². It is a rare finding³, and its presence essentially confirms the PTE diagnosis. Its prevalence is 4 to 20% of patients with PTE^{1,4}. The risk for mortality in patients with thrombus in transit

is significantly increased in comparison with the presence of isolated PTE⁵; the mortality rate can be as high as 50%⁶. Thrombus in transit clinical presentation in the right cavities is variable, ranging from mild respiratory symptoms to cardiogenic shock and sudden death⁷. The diagnosis is made with transthoracic echocardiogram, transesophageal echocardiogram, computed angiotomography⁸ and magnetic resonance imaging⁹. Recommended treatment alternatives include anticoagulation, percutaneous thrombectomy, thrombolytic therapy and surgical embolectomy, with the latter two being associated with higher survival (70.45% and 81.5%) in comparison with anticoagulation (47.7%). Without treatment, mortality is > 90%^{10,11}.

Correspondence:

*Luis Arboine-Aguirre
UMAE No. 34
Monterrey, NL, México
E-mail: luisarboine1986@gmail.com

Date of reception: 20-11-2015
Date of acceptance: 06-01-2016

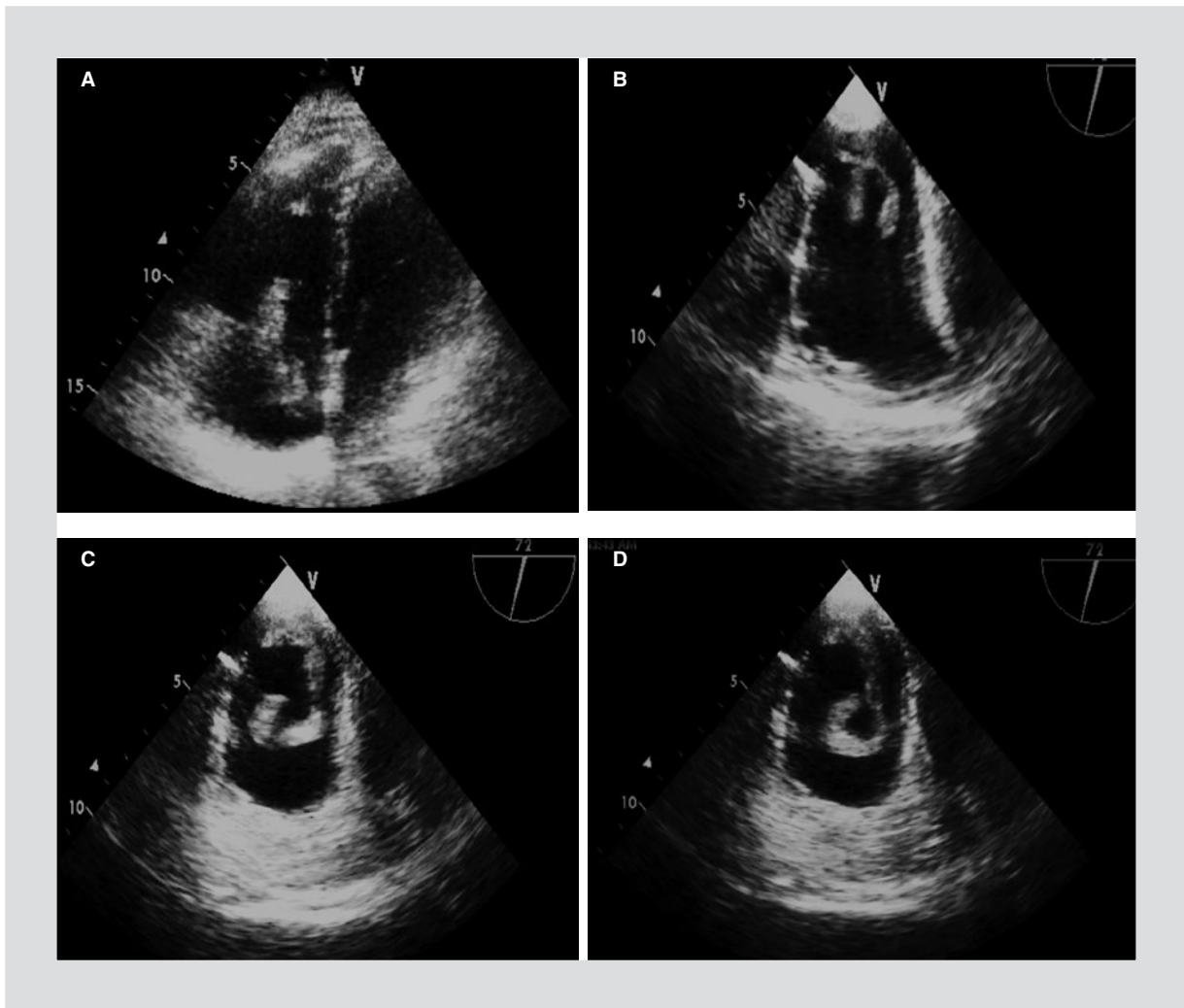


Figure 1. A: transthoracic echocardiogram showing a thrombus in the right atrium protruding towards the right ventricle. **B, C and D:** transesophageal echocardiogram showing a worm-like structure in the right atrium adhered to the Eustachian valve.

Clinical case

This is the case of a 50-year old male who attended the emergency department due to symptoms initiated 2 weeks prior with progressive dyspnea to the point of occurring with minimal effort, accompanied only by pleuritic chest pain. Portal vein thrombosis 3 years prior and active smoking stood out on his past medical history. Clinically, his blood pressure was 110/70 mmHg, heart rate 60/minute, respiratory rate 22/minute and arterial oxygen saturation of 95%. The electrocardiogram showed sinus rhythm, left anterior fascicular hemiblock and T-wave inversion at V1-V4. Laboratory results reported: B-type natriuretic peptide, 199.8 pg/mL (0-100); D-dimer, 854 ng/mL (0-500); and troponin, 0.04 ng/mL (0-0.40). Chest X-ray was not diagnostic.

The transthoracic echocardiogram showed a RV/LV ratio of 0.70:1 and an image in the right atrium protruding towards the right ventricle through the tricuspid valve, suspicious of thrombus in transit (Fig. 1). Transesophageal echocardiogram revealed pulmonary systolic pressure of 40 mmHg and minimal tricuspid regurgitation; inside the right atrium, an elongated, mobile structure, with winding course, of 90 x 8 mm in diameter, adhered to a remnant of the Eustachian valve, was observed (Fig. 1). Computerized angiography showed filling defects consistent with thrombi on segmental and subsegmental main branches (Fig. 2). The decision was made to perform thrombolysis with tenecteplase (TNK, 8,000 units IV over 5 seconds) and, subsequently, the patient was moved to the coronary care unit, with improvement of his clinical status. Low molecular weight heparin was started

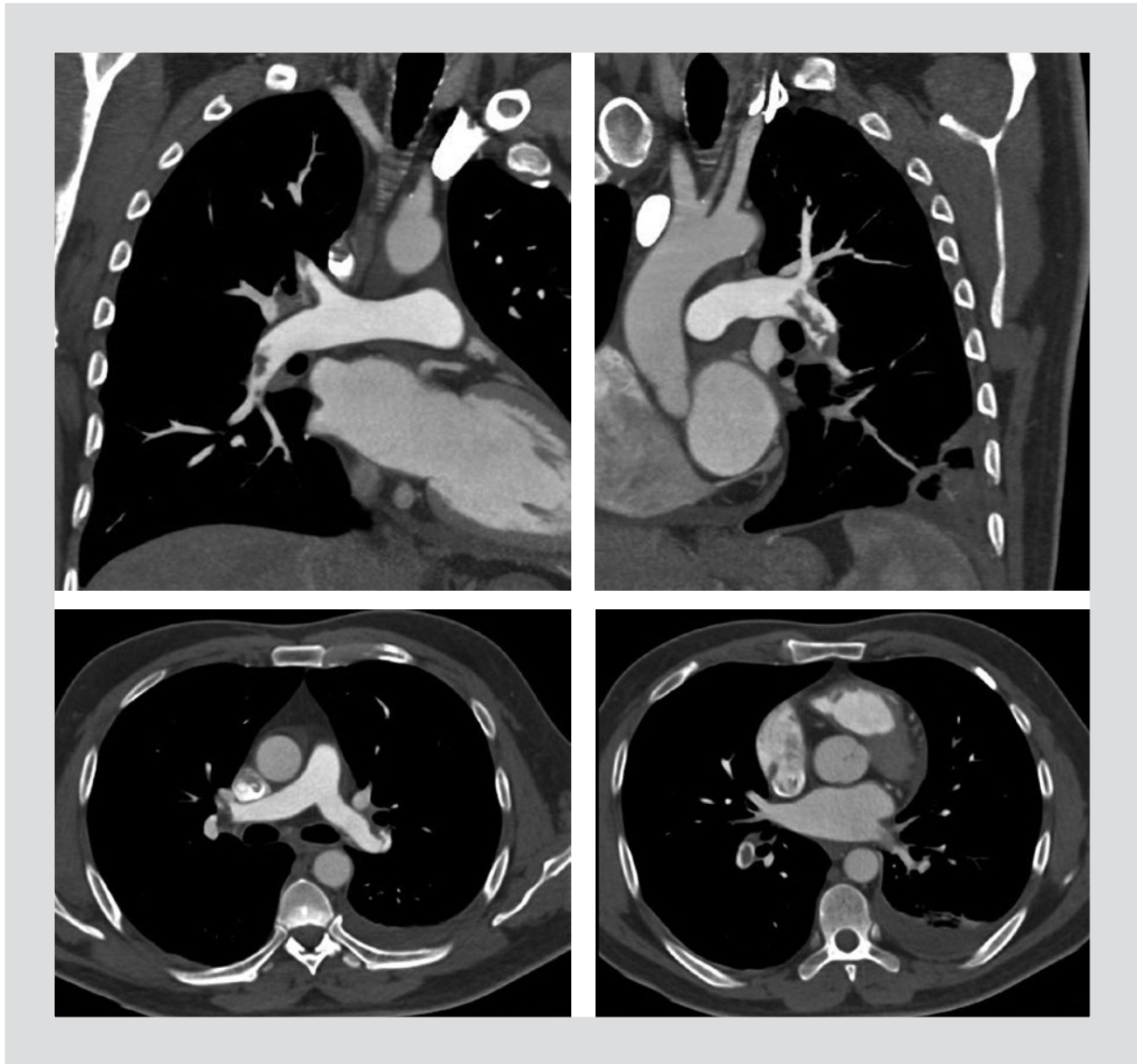


Figure 2. Pulmonary computed angiotomography showing partial filling defects in main, lobar and segmental branches, bilaterally.

and subsequently warfarin by oral route. Lower limb bilateral Doppler ultrasound showed no deep vein thrombosis.

Five days later, a new echocardiogram was performed, where no intracardiac masses or thrombi were identified. His general status was significantly improved and he was discharged at hospitalization sixth day, once therapeutic International Normalized Ratio (INR) was reached.

Discussion

Although thrombus in transit is an unusual condition, it is regarded as an extreme therapeutic emergency

owing to its high rate of mortality (> 44%). Any treatment delay could be lethal; in fact, 21.1% of patients die within the first 24 hours after admission. In spite of its high mortality, the treatment of choice is still not well defined. Published reports differ on treatment recommendations: some suggest surgical management and others thrombolytic agents' administration, anticoagulation therapy or use of interventional percutaneous techniques^{7,9}.

One series of 38 patients with thrombus in transit reported a mortality rate of 44.7%. Mortality according to therapeutic management used was 62.5% for heparin, 47.1% for surgery, 50% for interventional techniques and 22.2% for thrombolytic treatment¹³.

A meta-analysis of 177 cases reported an overall mortality rate of 27.1%, with a 100% rate for patients with no treatment, 28.6% for patients with anticoagulant therapy, 23.8% with thrombolytic treatment and 11.3% with surgical embolectomy⁵.

The International Cooperative Pulmonary Embolism Registry (ICOOPER) showed similar 3-month mortality rates with thrombolytic treatment, embolectomy or heparin (29%, 25% and 29%, respectively)¹². The most recent meta-analysis comprised 328 patients, and the reported mortality rate was 23.2%, which is lower than those previously obtained. Administered treatments were thrombolytic agents in 122 patients (37.2%), surgical embolectomy in 120 patients (36.6%), anticoagulation in 70 patients (21.3%), no treatment in 11 patients (3.4%) and interventional treatment in 5 patients (1.5%). Mortality rates in patients who received thrombolysis, surgical embolectomy and anticoagulation were 13.7%, 18.3% and 37.1%, respectively. The highest mortality occurred in patients with no treatment (90.9%). Owing to the modest number of patients treated with interventional techniques, this subgroup was not compared with the other treatment groups. There was no increase in the risk for complications with the use of thrombolytic therapy¹⁰.

Greco et al.¹⁴ analyzed the behavior of the thrombus by echocardiogram during human recombinant tissue plasminogen activator (rt-PA) infusion in 7 patients with thrombus in transit. They noted that lysis of the clot started between 45 and 60 minutes after treatment administration. Lysis occurred with progressive fragmentation in small particles, which migrated from the right cavities to the pulmonary circulation to finally disappear. After 2 hours of infusion, all echocardiographic parameters showed significant improvement. No adverse effects were documented during treatment and hospitalization, and there were no PTE recurrences, major bleeds or deaths.

The case of our patient was successfully managed with fibrinolytic therapy, with no treatment-related complications occurring.

In the literature, as far as we could review, we only found few reports on cases of thrombi in right cavities treated with TNK^{2,15-17}.

In conclusion, bolus-TNK was safe and efficacious in the treatment of this case of PTE complicated with thrombus in transit in the right cavities. Its availability in the emergency department, together to its easy and quick administration, make it an attractive thrombolytic agent in patients with thrombus in transit. Studying more patients treated with this thrombolytic regimen is required in order to corroborate this finding.

References

1. Konstantinides S, Torbicki A, Agnelli G, et al. Guidelines on the diagnosis and management of acute pulmonary embolism. *Eur Heart J*. 2014; 35:3145-6.
2. Shamkhani W, Jafar N, Narayanan S, et al. Right heart thrombus in-transit in patient with acute pulmonary embolism treated by thrombolytic therapy with tenecteplase. *International Journal of Medical Imaging*. 2015;3:11-5.
3. Pierre Justin G, Pierard LA. Management of mobile right heart thrombi: a prospective series. *Int J Cardiol*. 2005;99:381-8.
4. Romero I, Mendoca M, Cavalcanti R, et al. Right heart emboli-in-transit. Case report and literature review. *Arq Bras Cardiol*. 2008;90:e44-7.
5. Rose P, Punjabi N, Pearse D. Treatment of right heart thromboemboli. *Chest*. 2002;121:806-14.
6. Proano M, Oh JK, Frye RL, et al. Successful treatment of pulmonary embolism and associated mobile right atrial thrombus with use of a central thrombolytic infusion. *Mayo Clin Proc*. 1988;63:1181-5.
7. Bhargava M, Dincer E. Traveling thrombus in the right atrium: is it the final destination? *Case Rep Pulmonol*. 2012;2012:1-3.
8. Jammal M, Milano P, Cardenas R, et al. The diagnosis of right heart thrombus by focused cardiac ultrasound in a critically ill patient in compensated shock. *Crit Ultrasound J*. 2015;7:1-12.
9. Soga T, Sato Y, Matsumoto N, et al. Right atrial free-floating thrombus in a patient with massive pulmonary embolism: a case of 'emboli in transit'. *Int J Cardiol*. 2008;129:e66-8.
10. Athappan G, Sengodan P, Chacko P, et al. Comparative efficacy of different modalities for treatment of right heart thrombi in transit: a pooled analysis. *Vasc Med*. 2015;20:131-8.
11. Eid G, Gaspar J, Sandoval J, et al. Combined clot fragmentation and aspiration in patients with acute pulmonary embolism. *Chest*. 2008;134: 54-60.
12. Torbicki A, Gal'ie N, Covezzoli A, Rossi E, De Rosa M, Goldhaber SZ. Right heart thrombi in pulmonary embolism: results from the international cooperative pulmonary embolism registry. *J Am Coll Cardiol*. 2003;41: 2245-51.
13. Chartier L, Béra J, Delomez M, et al. Free floating thrombi in the right heart: diagnosis, management, and prognostic indexes in 38 consecutive patients. *Circulation*. 1999;99:2779-83.
14. Greco F, Bisignani G, Serafini O, et al. Successful treatment of right heart thromboemboli with IV recombinant tissue-type plasminogen activator during continuous echocardiographic monitoring: a case series report. *Chest*. 1999;116:78-82.
15. Nkoko C, Faucher O, Camus L, Flork L. Free floating right heart thrombus associated with acute pulmonary embolism: an unsettled therapeutic difficulty. *Case Rep Cardiol*. 2015;2015:1-4.
16. Sharma A, Udgire PP, Khan S, Goyal BK, Gautam S. Pulmonary thromboembolism and right heart thromboemboli - an experience with tenecteplase. *J Assoc Physicians India*. 2012;60:52-4.
17. Shankarappa R, Math R, Papaiah S, et al. Free floating right atrial thrombus with massive pulmonary embolism: near catastrophic course following thrombolytic therapy. *Indian Heart J*. 2013;65:460-3.