

## Application of cantharidin, podophyllotoxin, and salicylic acid in recalcitrant plantar warts. A preliminary study

Daniel López-López<sup>1\*</sup>, Carlos Agrasar-Cruz<sup>2</sup>, Adolfo Bautista-Casasnovas<sup>3</sup> and Carlos Javier Álvarez-Castro<sup>1</sup>

<sup>1</sup>Department of Health Sciences, Faculty of Nursing and Podology, Universidade da Coruña, Spain; <sup>2</sup>Department of Medicine, Faculty of Health Sciences, Universidade da Coruña, Spain; <sup>3</sup>Department of Pediatrics, Faculty of Medicine and Odontology, Universidad de Santiago de Compostela, Spain

### Abstract

**Introduction:** Plantar warts are often refractory to every kind of treatment and can prevail for decades in adults. We define as recalcitrant those warts that have persisted for more than 2 years, or after at least two treatment modalities. **Material and methods:** A total of 15 consecutive patients with recalcitrant plantar warts were included in this preliminary study. The treatment involved one or two sessions to apply the compounding comprised by 1% of cantharidin, 5% of podophyllotoxin and 30% of salicylic acid (CPS), with a 4-week interval between applications. **Results:** During the treatment and its subsequent six-month follow-up, complete eradication of the lesions was observed in all 15 patients; 8 (53.3%) required a single application of the solution and 7 (46.7%), two applications, with no side effects. Treatment-related patient satisfaction was measured using a 10-cm long visual analogue scale (VAS), with an average score of  $9.73 \pm 0.46$ ; all patients stated that they would proceed with the treatment again if necessary. **Conclusions:** Topical treatment with the compounding is safe and efficacious, and represents a promising therapeutic modality when applied on recalcitrant plantar warts. (Gac Med Mex. 2015;151:14-8)

**Corresponding author:** Daniel López López, daniellopez@udc.es

**KEY WORDS:** Cantharidin. Papillomavirus. Recalcitrant plantar wart. Wart treatment.

### Introduction

Warts are very common viral infections of the skin and are caused by the human papilloma virus (HPV), which is responsible for these dermal lesions and represents a very large group of closely related viruses, with more than 100 types. HPVs infect both the skin and the mucosae, and many of them correspond to different clinical phenotypes<sup>1</sup>.

These infections are often frustrating both for patients and clinicians<sup>2,3</sup>, since they affect the patient's quality of life, causing shame, fear of being negatively evaluated by others and frustration due to their persistence and recurrence<sup>4,5</sup>.

Generally, these proliferations are refractory to very different treatments and can persist for decades in adults<sup>6</sup>, hence the definition of recalcitrant warts when they persist for more than 2 years or after at least two different treatment modalities. Therefore, the treatment of recalcitrant plantar warts is assessed separately from that of common warts<sup>7,8</sup>.

Currently, there is no cure for the HPV infection<sup>9</sup> and current therapy is aimed to suppress signs and symptoms; there is a lack of a single or completely effective treatment for all patients affected at a general level and especially on the feet<sup>10</sup>.

Recurrence often occurs with the vast majority of treatments and the treatment algorithm is quite varied; those that are commonly used are associated with surgery, electrocoagulation, cryotherapy with liquid nitrogen and

#### Correspondence:

\*Daniel López López  
Departamento de Ciencias da Saúde  
Facultad de Enfermería e Podología, Universidade da Coruña  
Campus Universitario de Esteiro, s/n  
15403, Ferrol, La Coruña, Spain  
E-mail: daniellopez@udc.es

The authors declare not having any economic conflict of interests. No funding has been received for the research and writing of this article

Date of reception in modified version: 16-10-2013

Date of acceptance: 13-02-2014

laser vaporization<sup>11</sup>, although, in most cases, topical agents such as salicylic, nitric and monochloroacetic acid and cytotoxic agents such as bleomycin sulphate, podophyllotoxin and 5-fluorouracil are used<sup>12</sup>.

The lack of controlled studies specifically focused on the treatment of warts (there are even less on the treatment of plantar warts<sup>13,14</sup>) highlights the need for research to be conducted in this field, although, recently, topical treatment using the compounding comprised by 1% of cantharidin, 5% of podophyllotoxin and 30% of salicylic acid (CPS) has been reported to have a very elevated rate of cure<sup>15</sup>.

Cantharidin is a blister agent produced by beetles of the *Meloidae coleoptera* family. The substance is known as Spanish fly. In Southern Europe, it is prepared using the *Lytta vesicatoria* species and has a long history both in popular and traditional medicine<sup>16</sup>. In dermatology, the compounding with this topical solution has been used as a vesicant for the treatment of warts and *Molluscum contagiosum* since 1958<sup>17,18</sup>. As the formation of blisters occurs within the epidermis, it lacks adverse reactions<sup>19</sup>. The use of this agent is not associated with any type of discomfort, although the formation of blisters may produce pain<sup>3</sup>.

Healing rates with this topical agent are high: at a general level, above 80%; for common, plantar and periungual warts<sup>14</sup>, and particularly in the feet, complete clearance has been achieved in 95.8% of the cases<sup>15</sup>. This is an extremely high cure rate compared with other treatments<sup>20,21</sup>. However, there is scarce information in the literature on the efficacy of the topical treatment with the compounding consisting of 1% cantharidin, 5% podophyllotoxin and 30% salicylic acid (CPD) in the treatment of recalcitrant plantar warts.

Based on this background, the cantharidin topical solution is likely to be also an effective and safe treatment when these dermal infections persist. In this preliminary study, the treatment and a 6-month follow-up by the same clinician of the complete process concerning the abovementioned treatments, the number of treatment sessions, adverse effects due to the treatment, patient satisfaction and rate of recurrence are described.

## Material and methods

### Patients

A total of 15 consecutive patients with recalcitrant plantar warts in different limited areas of the feet were seen in a single foot orthopedics and surgery outpatient center, where they were recruited over a six-month

period. The diagnostic was made based on clinical appearance<sup>22</sup> in most cases, with biopsies being performed in two problematic patients.

Exclusion criteria included pregnancy or breastfeeding, immunosuppression, use of medications, known sensitivity to any of the components of the study solution and dermatologic conditions at the site of treatment application, such as eczema and psoriasis. Patients with unrealistic expectations or fear in relation to the treatment potential and those unable to tolerate and/or comply with treatment recommendations were excluded from the study. All patients gave their written informed consent prior to inclusion in the study<sup>18</sup>, and the ethical principles for medical investigation in human beings set forth by the Medical Declaration of Helsinki were preserved.

The information received by the patients in the informed consent form clarified details on the procedure, expectations after treatment and possible relapses that had been discussed in visits before starting the treatment. All participants were warned that the medication produced blisters on the lesion, which could be painful. Adequate painkillers were prescribed in order to palliate the pain, in case its use was necessary during the treatment.

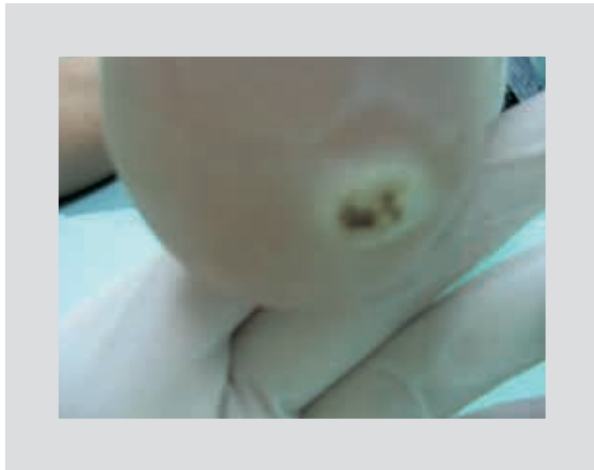The patient was provided with the telephone number of the investigator and was able to call him any time, for any clarification or doubt, or if adverse reactions occurred, such as burning sensation or discomfort on the feet, fever, diarrhea or vomiting.

### Procedure

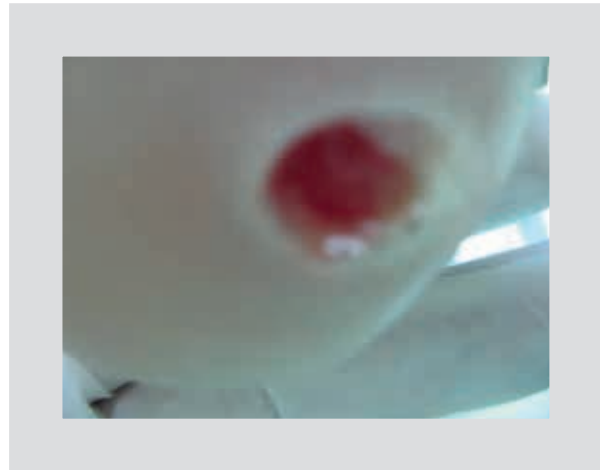The technique followed in the present study was the one described by Becerro de Bengoa Vallejo et al.<sup>15</sup>, which involved cleaning and disinfecting the zone and delaminating the recalcitrant plantar wart with a number 3 scalpel handle and a number 15 blade<sup>15</sup>.

Next, the compounding of the topical preparation consisting of cantharidin (1%), salicylic acid (30%), podophyllotoxin (5%) and 2 ml of flexible collodion was applied with a swab on the recalcitrant plantar wart without surpassing the margins of the lesion, and the solution was allowed to dry on the area for a few seconds. Then, it was covered with a porous dressing until the programmed examination.

The patient returned for examination at 24 or 48 h. In the cases where excessive discomfort was generated, the bandage was removed earlier and the clinician could observe the formation of a blister in the zone where the topical preparation had been applied (Fig. 1). After removing the dressing, the content of the blister



**Figure 1.** Blister formed at 48 h of solution application



**Figure 2.** The blister covering the recalcitrant plantar wart is debrided.

covering the recalcitrant plantar wart was appreciated. Next, the clinician proceeded to drain the vesicle and debride it with a scalpel (Fig. 2).

The result was the removal and total clearance of the lesion (Figs. 3 and 4). Subsequent ambulatory treatment was based on topical application of antiseptics, wound-healing agents or antibiotic ointments in order to prevent infection of the lesion, and on the use of a bandage for subsequent protection.

After 15 or 20 days, if the zone was completely healed and there were no signs of the plantar wart, the patient was discharged (Fig. 5). A control visit at the 6<sup>th</sup> month confirmed the definitive resolution of the lesion.

In cases where plantar wart clinical signs persisted after 15 or 20 days –time established to be necessary for the skin to epithelialize and regenerate– a second solution application session was carried out following

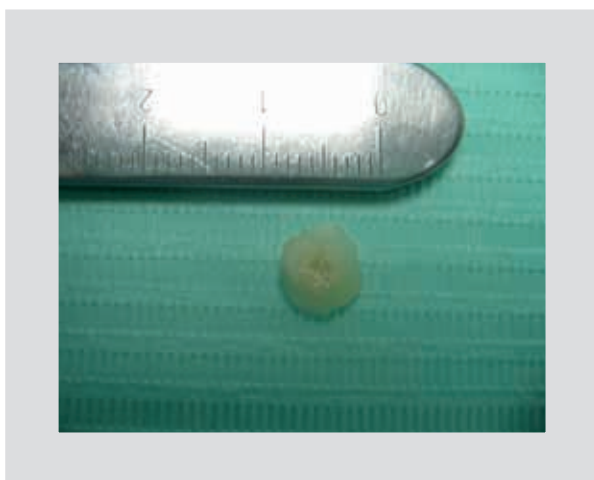
the same application protocol described for the first session.

## Results

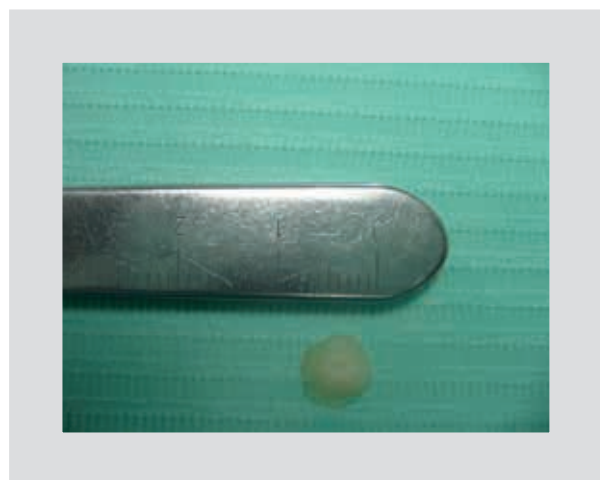
A total of 15 patients were included in the study and all of them completed the treatment course. Among the study population there were 8 male (53.3%) and 7 female patients (46.7%), with an average age of  $27.53 \pm 5.67$  years. Demographics and clinical data of the patients are summarized in table 1.

At the beginning of the study, the patients had a total of 24 lesions in different limited areas of the feet, 11 of which (45.83%) were located in the forefoot, 5 (20.83%) in the midfoot and 10 (33.33%) in the rearfoot zones.

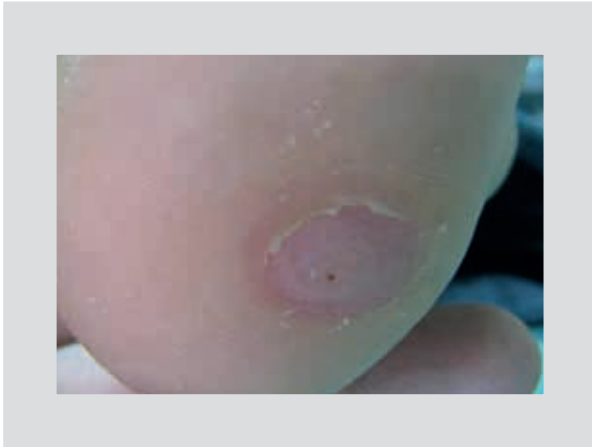Average duration of the lesions was  $26.53 \pm 2.36$  months. All the patients had received previous treatments



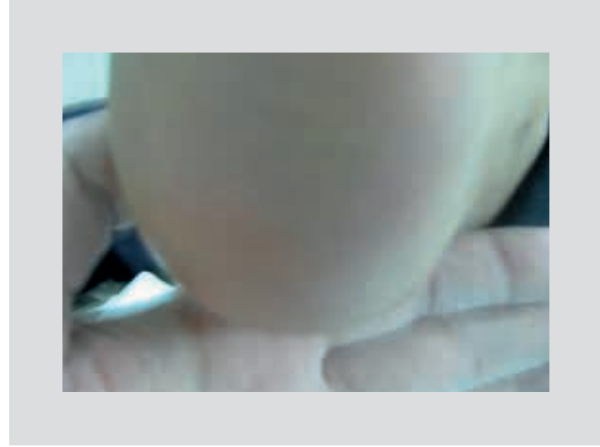
**Figure 3.** Appearance of the removed recalcitrant plantar wart on a dorsal view.



**Figure 4.** Appearance of the removed recalcitrant plantar wart on a plantar view.



**Figure 5.** Appearance once the tissue has epithelialized 3 weeks after the preparation was applied.



**Figure 6.** Appearance of the area 24 weeks after the preparation was applied.

(Table 1). Response to treatment and healing of lesions after the cantharidin solution application were of 100%, without the occurrence of adverse reactions.

After the first treatment application session, no patient worsened or experienced pain when walking. All lesions disappeared completely with a single applica-

tion of the topical treatment in 8 patients (53.3%), and 7 (46.66%) had also a complete response when the solution was applied twice. All patients showed clinical healing within 8 weeks and the number of sessions required for the complete clearance of the recalcitrant plantar warts was  $1.47 \pm 0.52$ .

**Table 1.** Demographic and clinical data of the 15 patients

Age	Sex	Site and number of lesions	Time of evolution (months)	Previous treatments	Treatment duration (weeks)	Number of sessions	Satisfaction VAS (0-10)
20	M	2 forefoot	24	2	4	1	10
25	F	1 forefoot	30	2	5	2	10
30	F	2 rearfoot	26	2	6	1	10
25	M	2 forefoot	28	2	4	2	9
26	M	1 midfoot	23	2	4	1	10
29	F	1 midfoot	24	2	8	2	9
18	F	2 forefoot	29	2	4	1	10
29	F	1 forefoot	26	2	4	1	9
33	M	1 rearfoot	28	2	8	2	10
41	F	1 midfoot	24	2	4	1	9
26	M	2 midfoot	24	2	7	2	10
29	M	1 rearfoot	30	1	5	2	10
27	M	3 rearfoot	26	2	4	1	10
22	F	2 forefoot	28	2	8	2	10
33	M	2 rearfoot	28	2	4	1	10

Treatment-related patient satisfaction was assessed at the end of therapy using a VAS. For this, the patient was asked to point out in a 10-cm long line the degree of satisfaction, where 1 meant not satisfied at all and 10, completely satisfied<sup>23</sup>. The obtained score was  $9.73 \pm 0.56$  points and all patients stated that they would proceed again with the topical treatment tested in the study if necessary, since the treatment was relatively painless, safe and effective.

## Discussion

The contribution of our preliminary study provides with superior remission and satisfaction rates than those in other previous studies that have shown inferior results with other therapies<sup>24,25</sup>, showing that this is a reliable therapeutic alternative to be taken into account in patients with chronic lesions that are perceived as a problem for health, since they affect their quality of life and autonomy when they occur in hands and feet<sup>26</sup>, largely due to the anti-esthetic appearance, pain and concerns of the infection being transmitted at the general level to other people and especially to different zones of the body<sup>5</sup>.

Topical application of the compounding with chemical agents such as cantharidin, podophyllotoxin and salicylic acid on recalcitrant plantar warts is a simple and safe method, applicable in the ambulatory setting of the daily practice of a general practitioner or a specialized physician and it is generalizable to a wide spectrum of patients, as proposed by other authors<sup>15</sup>.

The lack of important undesirable effects that are typical with other techniques, such as scarring, infections or toxicity attributed to accidental ingestion of the treatment<sup>18</sup>, is an advantage to be taken into account for its use<sup>19</sup>.

## Conclusions

This preliminary study shows that application of the compounding comprising 1% of cantharidin, 5% of podophyllotoxin and 30% of salicylic acid (CPS) is a safe and effective therapy and a useful tool for the treatment of recalcitrant plantar warts in limited areas and exclusively, with a healing rate of 100% and without recurrences. The procedure is well tolerated, it doesn't produce adverse reactions such as scarring and it constitutes a treatment option to be highlighted in cases of failure of other treatments.

## Acknowledgements

The authors wish to thank all the people who participated in the study, followed the treatment recommendations and signed the informed consent form.

## Bibliography

1. Lio P. Warts, molluscum and things that go bump on the skin: A practical guide. *Arch Dis Child Educ Pract Ed*. 2007;92(4):119-24.
2. Chern E, Yu-SWen Cheng. Treatment of recalcitrant periungual warts with cimetidine in pediatrics. *J Dermatol Treat*. 2010;21(5):314-6.
3. Lipke MM. An Armamentarium of Wart Treatments. *Clin Med Res*. 2006;4(4):273-93.
4. Ciconte A, Campbell J, Tabrizi S, Garland S, Marks R. Warts are not merely blemishes on the skin: A study on the morbidity associated with having viral cutaneous warts. *Australas J Dermatol*. 2003;44(3):169-73.
5. Fuchs SM, Fluhr W, Bankova L, Tittelbach J, Hoffmann G, Elsner P. Photodynamic therapy (PDT) and waterfiltered infrared A (wIRA) in patients with recalcitrant common hand and foot warts. *Ger Med Sci*. 2004;2:Doc08.
6. Kaçar N, Ta,cli L, Korkmaz S, Ergin S, Erdoğan B.S. Cantharidin-podophyllotoxin-salicylic acid versus cryotherapy in the treatment of plantar warts: a randomized prospective study. *J Eur Acad Dermatol Venereol*. 2012;26(7):889-93.
7. Rivera A, Tying SK. Therapy of cutaneous human papilloma-virus infections. *Dermatol Ther*. 2004;17(6):441-8.
8. Glass AT, Solomon BA. Cimetidine therapy for recalcitrant warts in adults. *Arch Dermatol*. 1996;132(6):680-2.
9. Stockfleth E. Human papilloma virus infections. En: Burgdorf WHC, Plewig G, Wolff HH, Landthaler M, eds. *Braun-Falco's Dermatology*. 3.a ed. Italia: Springer; 2009. p. 64-73.
10. Kuykendall-Ivy TD, Johnson SM. Evidence-based review of management of nongenital cutaneous warts. *Cutis*. 2003;71(3):213-22.
11. El-Tonsy MH, Anbar TE, El-Domyati M, Barakat M. Density of viral particles in pre and post Nd: YAG laser hyperthermia therapy and cryotherapy in plantar warts. *Int J Dermatol*. 1999;38(5):393.
12. Cance DJ, Gadner SD. Papovaviruses: Papillomaviruses and Polyomaviruses, in Principles and Practice of Clinical Virology. En: Zuckerman AJ, Banatvala JE, Pattison JR, eds. Nueva York: John Wiley & Sons; 1997. P. 491.
13. Gibbs S, Harvey I. Topical treatments for cutaneous warts. *Cochrane Database Syst Rev*. 2006;(3):CD001781.
14. Yang F, Qin X, Cheng Z, Xie S. Intralesional pingyangmycin treatment for resistant plantar warts. *Dermatology*. 2010;220(2):110-3.
15. Becerro de Bengoa Vallejo R, Losa Iglesias ME, Gómez-Martín B, Sánchez Gómez R, Sáez Crespo A. Application of cantharidin and podophyllotoxin for the treatment of plantar warts. *J Am Podiatr Med Assoc*. 2008;98(6):445-50.
16. Day RM, Harbord M, Forbes A, Segal AW. Cantharidin blisters: a technique for investigating leukocyte trafficking and cytokine production at sites of inflammation in humans. *J Immunol Methods*. 2001;257 (1-2):213-20.
17. Epstein WL, Kligman AM. Treatment of warts with cantharidin. *AMA Arch Derm*. 1958;77(5):508-11.
18. Moed L, Shwayder TA, Chang MW. Cantharidin revisited. *Arch Dermatol*. 2001;137(10):1357-60.
19. Silverberg NB, Sidbury R, Mancini AJ. Childhood molluscum 5. contagiosum: Experience with cantharidin therapy in 300 patients. *J Am Acad Dermatol*. 2000;43(3):503-7.
20. Canpolat F, Cemil BC, Eskioğlu F. Liquid nitrogen cryotherapy of plantar verrucae: cryoblast is more effective than the cryo-spray. *Eur J Dermatol*. 2008;18(3):341-2.
21. Ahmed I, Agarwal S, Ilchysyn A, Charles-Holmes S, Berth-Jones J. Liquid nitrogen cryotherapy of common warts: cryo-spray vs. cotton wool bud. *Br J Dermatol*. 2001;144(5):1006-9.
22. Kartal Durmazlar SP, Atacan D, Eskioğlu F. Cantharidin treatment for recalcitrant facial flat warts: a preliminary study. *J Dermatolog Treat*. 2009;20(2):114-9.
23. Hernando T, Rico-Villademoros F. Documentos esenciales para el desarrollo de un ensayo clínico. En: Hernández G, Moreno A, Zaragoza F, Porras A, eds. *Tratado de Medicina Farmacéutica*. Madrid: Panamericana; 2010. p. 211-22.
24. Lim JT, Goh CL. Carbon dioxide laser treatment of periungual and subungual viral warts. *Australas J Dermatol*. 1992;33(2):87-91.
25. Logan RA, Zachary CB. Outcome of carbon dioxide laser therapy for persistent cutaneous viral warts. *Br J Dermatol*. 1989;121(1):99-105.
26. Oni G, Mahaffey PJ. Treatment of recalcitrant warts with the carbon dioxide laser using an excision technique. *J Cosmet Laser Ther*. 2011; 13(5):231-6.