

## Subtotal supracricoid laryngectomy (SCSL): the importance of the histopathological analysis

Manuel García-Sánchez<sup>1</sup>, Elizabeth Romero-Durán<sup>2</sup>, Alejandra Mantilla-Morales<sup>2</sup>  
and José Francisco Gallegos-Hernández<sup>2\*</sup>

<sup>1</sup>Department of Head & Neck Tumors; <sup>2</sup>Department of Pathology, Oncology Hospital, Centro Medico Nacional Siglo XXI, Instituto Mexicano del Seguro Social, México, D.F.

### Abstract

*The purpose of conservative surgical treatment of laryngeal cancer (LCa) is to obtain cancer control with preservation of the laryngeal function. This preservation should be understood as maintaining the patient's ability to ventilate in the normal way without tracheotomy or aspiration and preserving intelligible speech. This goal is achieved by maintaining a balance between two fundamental aspects: adequate patient selection (based on tumor extension and preoperative laryngeal function) and adequate histopathological analysis of the surgical specimen. Supracricoid subtotal laryngectomy (SCSL) is the voice-preserving surgical technique that oncologically offers the best possibility for control in patients with locally advanced laryngeal cancer. An adequate histopathological analysis enables staging and selection of candidate patients for adjuvant therapy, thus avoiding unnecessary treatments, and allows for a follow-up and surveillance program to be designed based on risk factors. The purpose of the present manuscript is to highlight key points of the histopathological assessment of the SCSL specimen. Adequate communication between surgeon and pathologist, offering complete information on clinical preoperative assessment and knowledge of the key points revealed by histopathological evaluation of the surgical specimen (sites of probable tumor leakage and surgical resection margins) are fundamental parameters to achieve an adequate histopathological assessment of the surgical specimen. (Gac Med Mex. 2015;151:96-9)*

**Corresponding author:** José Francisco Gallegos Hernández, gal61@prodigy.net.mx; www.govame.com

**KEY WORDS:** Laryngeal cancer. Partial laryngectomy. Laryngectomy.

### Introduction

Squamous cell carcinoma is the neoplasm most commonly originating in the upper aerodigestive tract (UADT) in general and in the larynx in particular. GLOBOCAN<sup>1</sup>, in its last report published in 2008,

calculates that 151,000 new laryngeal cancer (LCa) cases are diagnosed per year in the entire world, which places it in the 17<sup>th</sup> place among all solid neoplasms, with a prevalence of 1.1% and an age-standardized mortality rate of 1.2/100,000.

In Mexico, the General Direction of Epidemiology reported in 2008 the record of 855 new LCa cases with a rate of 0.8 per 100,000 inhabitants, 0.2% of total deaths and 1.3% of total tumors<sup>2</sup>.

As with the rest of UADT-originated carcinomas, its cause is closely related to the consumption of tobacco<sup>3,4</sup>.

The larynx has a different embryologic origin, which allows for it to be divided into three regions: supraglottic

#### Correspondence:

\*José Francisco Gallegos Hernández  
Departamento de Tumores de Cabeza y Cuello  
Hospital de Oncología  
Centro Médico Nacional Siglo XXI  
Instituto Mexicano del Seguro Social  
Cuauhtémoc, 330  
Col. Doctores, C.P. 06725, México, D.F.  
E-mail: gal61@prodigy.net.mx  
www.govame.com

Date of reception: 29-03-2014

Date of acceptance: 08-12-2014

(above the vocal cords), glottic (vocal cords and anterior commissure) and subglottic (below the cords). The site where this neoplasm most frequently occurs is the glottic or cord region, from where it advances to invade mainly the supraglottic region<sup>5</sup>.

The treatment of LCa depends on the stage of the neoplasm and the patient's general conditions. The aim of therapy is to achieve an adequate balance between cancer control and preservation of phonation and ventilation by the natural pathway.

In patients in whom laryngeal function preservation is attempted, the cricoarytenoid unit should be regarded as the functional unit of the larynx. This unit is formed by the arytenoid cartilage, the cricoid cartilage, the interarytenoid muscles and the laryngeal inferior and laryngeal superior nerves. Preservation of these structures during functional surgery allows for physiological success; this unit allows for adequate phonation and deglutition without aspiration<sup>5,6</sup>.

In early neoplasms (T1-2), treatment is unimodal (endoscopic surgery with laser resection, radical radiotherapy to the voice box and, eventually, voice-preserving open surgery), but in locally or locoregionally advanced neoplasms, treatment is often mutilating, which implies removal of the voice box, definitive tracheotomy and voice rehabilitation with either phoniatric or prosthetic methods. However, there are patients at "intermediate stages", i.e., patients with tumors that, in spite of being locally advanced, do not have important phonation or deglutition dysfunction and have a voice with an acceptable quality in spite of the neoplasm, and adequate cord and/or arytenoid mobility. These patients are usually staged as T2, T3 and some early T4, either with or without cervical lymph-node metastases. In these patients, usual therapy is total laryngectomy (TL) followed by radiotherapy or chemotherapy, according to prognostic factors. Supracricoid subtotal laryngectomy with laryngeal reconstruction with cricohyoidoepiglottopexy (SCSL + CHEP) has been designed for this group of patients. The purpose of this treatment is the same that guides the therapeutics of LCa: to achieve a balance between natural phonation-ventilation and satisfactory oncologic control, obtaining a cure rate similar to that of TL followed by radiotherapy<sup>6-9</sup>.

SCSL + CHEP is indicated in patients with advanced neoplasms but adequate laryngeal functionality; patients that, otherwise, under the perspective of standard treatment, are considered candidates to TL. SCSL + CHEP is a step prior to TL and one last attempt to preserve laryngeal function<sup>8-10</sup>.

To achieve this goal, not only an adequate patient selection is required<sup>9</sup>, but also an adequate assessment of the surgical specimen. This allows for complete removal of the tumor to be ensured and it is a key point to reduce the rate of neoplastic relapse.

The purpose of this manuscript is to highlight important and key points for an adequate histopathological examination of the SCSL surgical specimen in patients with laryngeal squamous-cell carcinoma.

## SCSL


Initially described by Majer et al.<sup>11</sup> and popularized by Piquet in Lille (France)<sup>12</sup>, this technique is considered as a safe and functional alternative prior to TL in patients with locally advanced laryngeal cancer. It is a conservative procedure designed for patients with tumors invading the paraglottic space but with preserved ipsilateral arytenoid cartilage mobility, for patients with tumors of the anterior commissure penetrating into the submucous layer, even with incipient infiltration of the internal face of the thyroid cartilage keel and the cartilaginous portion of the hyothyroepiglottic space (HTES), and for patients with tumors invading the epiglottic petiole, without reaching its laryngeal face, without massive invasion of the HTES or with invasion into the lower third of the epoglottis without suprahyoid invasion<sup>10</sup>.

This technique is contraindicated in tumors with subglottic infiltration, arytenoid fixation, bilateral cord fixation, massive topographic invasion of the HTES, significant infiltration of the thyroid cartilage and extralaryngeal tumors<sup>10</sup>.

Prognosis for patients undergoing SCSL depends on the findings obtained in the histological assessment of the specimen. One of the most important factors for local recurrence prognosis is the surgical margins status. The presence of tumor infiltration in the section margin is associated with local recurrence in 22-70% of cases; the presence of dysplasia in the surgical margins is associated with recurrence of the disease in a shorter period than if margins are free of malignancy<sup>13,14</sup>.

Identification of prognostic factors in the surgical specimen requires a systematic assessment<sup>15</sup> that allows for the size of the tumor, the presence or not of tumor infiltration into neighboring structures and neoplastic infiltration through different laryngeal anatomical spaces to be identified.

Lateral supraglottic tumors can invade the HTES; central supraglottic neoplasms, the supraventricular



**Figure 1.** Subtotal laryngectomy specimen with adequate orientation for histological study.

paraglottic space; and glottic and subglottic lesions, the infraventricular paraglottic space. Infiltration into the anterior commissure occurs in the insertion region of the cricothyroid ligament, which is a site of laryngeal weakness and from where it can advance towards the extralaryngeal region and destroy the keel of the thyroid cartilage.

### Recommendations for the management of specimens recovered from the SCSL procedure

The first recommendation is to identify the anatomical structures of the specimen to be sent. The specimen must be sent for histopathological evaluation with an adequate orientation with regard to anatomical structures and to the site of the tumor, with a scheme or drawing indicating the site where the tumor originated from, as well as the section margins and information on preoperative laryngeal kinetics (cord and arytenoid mobility).

The SCSL specimen includes the thyroid cartilage and the entire bilateral paraglottic space, both vocal cords, both Morgagni's ventricles, both ventricular bands, the anterior commissure, the epiglottic petiole sectioned precisely at its limit with the upper end of

the thyroid cartilage (suprathyroid portion) and may or may not include the arytenoid cartilage at the same side of the cord with neoplasm (Fig 1).

Surgical margins are identified and stained with different colors. The upper margin corresponds to the epiglottal petiole mucosa; the lower, to the mucosa that covers the upper end of the cricoid cartilage at its limit with the thyroid cartilage (cricothyroid membrane); and the posterior, to the posterior segment of the vocal cord in the cricovocal ligament. Occasionally, the ipsilateral arytenoid cartilage is included.

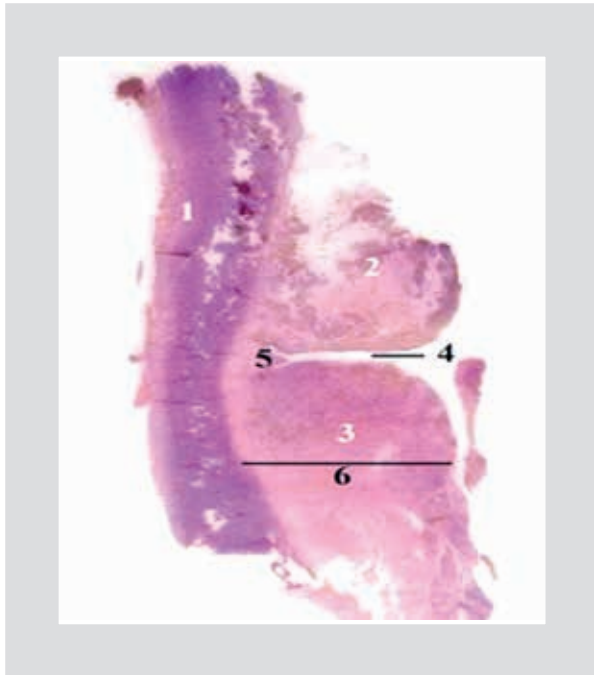
The tumor should be measured on the fresh specimen, as well as its distance from the surgical margins; its location is to be identified, as well as its longitudinal and horizontal extension. The specimen is fixed in formalin at 10% for 24 h. 3-mm sagittal cuts are performed and photographed for comparison with histological sections; if the thyroid cartilage is calcified, cuts can be made with a saw or heavy duty scissors and it should be decalcified for 24 h. An approximately 3-4 mm wide cut, parallel to the posterior edge is performed, which should be made length-wise to increase the surface to be assessed.

The performed sagittal cuts allow for the upper and lower surgical limits, the band and vocal cord, the ventricle, the paraglottic space and the thyroid cartilage to be assessed in a single section; the central cut, the anterior commissure; and the most posterior cut, the posterior third of the vocal cord (cord-arytenoid region) or the arytenoid cartilage (Fig. 2). Each section is assessed for tumor infiltration or not into the referred structures.

All sagittal sections must be included for histopathological analysis. In the microscopic evaluation of the specimen, histological type, degree of differentiation, and maximal thickness of the neoplasm has to be determined, as well as infiltration into the paraglottic space, infiltration to the anterior commissure and thyroid cartilage, vascular invasion, perineural invasion, presence of dysplasia or carcinoma in situ in the adjacent mucosa and, finally, surgical margins status has to be corroborated. A positive margin is considered when neoplastic cells are in contact with the ink of the surgical edge<sup>16</sup>.

Histopathological report of the SCSL specimen analysis should include:

- Sent specimen and type of performed procedure.
- Localization of the neoplasm (anatomical sites infiltrated by the tumor).
- Histological type.
- Histological grade.



**Figure 2.** Histological section of the subtotal laryngectomy specimen. 1: thyroid cartilage; 2: ventricular band; 3: vocal cord; 4: Morgagni's ventricle; 5: bottom of ventricle and 6: paraglottic space.

- Size of the tumor.
- Thickness of the tumor (vertical growth into the paraglottic space) measured in millimeters from the basal membrane of the lining epithelium.
- Extension of the neoplasm.
- Infiltration or not of anterior commissure.
- Infiltration or not of thyroid cartilage.
- Vascular invasion.
- Perineural invasion.
- Presence or absence of dysplasia or carcinoma in situ in adjacent mucosa.
- Surgical margins status; the sites where tumor infiltrated section margins can be found more frequently are the junction of the vocal cord with the arytenoid mucosa (posterior section site) or the arytenoid itself if it was included in the surgery; the presence of tumor in it implies extension of the tumor to the interarytenoid region and very high risk of tumor residual in the remnant arytenoid; other size with risk is the mucosa under the anterior commissure, which is the zone of the inferior cut where the limit of the glottis with the subglottis is found (mucosa below the vocal cords); the presence of tumor in this region implies subglottic tumor infiltration.

## Conclusions

SCSL is a treatment alternative in patients with locally advanced squamous-cell carcinoma of the larynx with satisfactory laryngeal function. The selection of candidate patients to this technique is based on three points: identification of laryngeal sites invaded by the tumor, assessment of laryngeal functionality prior to the intervention and histopathological analysis of the surgical specimen.

Histological analysis of the specimen requires close communication between surgeon and pathologist in order to offer the most possible information with regard to tumor status, laryngeal kinetics and section margins to be analyzed. Adequate staging of the neoplasm depends on this study an, from which we will be able to design the monitoring program or an eventual edjuvant therapy. An inadequate pathological assessment can lead to unnecessarily redo surgery in the patient, with the consequent mutilation, or to offer postoperative radiotherapy, with the consequent function detriment, without being strictly necessary.

## References

1. Ferlay J, Shin HR, Bray F, Forman D, Mathers C, Parkin DM. Estimates of worldwide burden of cancer 2008: GLOBOCAN 2008. *Int J Cancer*. 2010;127(12):2893-917.
2. SINAIS/SINAVE/DGE/SALUD. Perfil epidemiológico de los tumores malignos en México. 200.8 [Internet] Disponible en: [www.sinais.salud.gob.mx](http://www.sinais.salud.gob.mx).
3. Gallegos-Hernández JF. El cáncer de cabeza y cuello. Factores de riesgo y prevención. *Cir Ciruj*. 2006;74:187-93.
4. Chu EA, Kim YJ. Laryngeal cancer: Diagnosis and preoperative work-up. *Otolaryngol Clin N Am*. 2008;41(4):673-95.
5. Agrawal N, Ha PK. Management of early-stage laryngeal cancer. *Otolaryngol Clin N Am*. 2008;41(4):757-69.
6. Gallegos-Hernández JF. Cirugía parcial de laringe, técnica y resultados. *Cir Ciruj*. 2010;78:351-455.
7. Rodrigo JP, Coca-Pelaz A, Suárez C. The current role of partial surgery as a strategy for functional preservation in laryngeal carcinoma. *Acta Otorrinolaringol Esp*. 2011; 62(3): 231-8.
8. Tufano R, Stafford E MD. Organ preservation surgery for laryngeal cancer. *Otolaryngol Clin N Am*. 2008;41(4):741-55.
9. Chawla S, Carney AS. Organ preservation surgery for laryngeal cancer. *Head Neck Oncol*. 2009;1:12.
10. Gallegos-Hernández JF, Minauro-Muñoz GG, Arias-Ceballos H, Hernández-Sanjuan M, Flores-Díaz R, Resendiz-Colosía J. [Partial pharyngolaryngectomies for treatment of pharyngolaryngeal cancer]. *Cir Cir*. 2008;76(3):213-7.
11. Majer EH, Rieder W. [Experiences with cricohioidopexy]. *Monatsschr Ohrenheilkd Laryngorhinol*. 1972;106(7):389.
12. Piquet JJ. Functional laryngectomy (cricohioidopexy). *Clin Otolaryngol Allied Sci*. 1976;1(1):7-16.
13. Gallo A, Manciocco V, Tropiano ML, et al. Prognostic value of resection margins in supracricoid laryngectomy. *The Laryngoscope*. 2004; 114(4):616-621.
14. Gallo A, Manciocco V, Simonelli M, Pagliuca G, D'Arcangelo E, de Vincentis M. Supracricoid partial laryngectomy in the treatment of laryngeal cancer: Univariate and multivariate analysis of prognostic factors. *Arch Otolaryngol Head Neck Surg*. 2005;131(7):620-5.
15. Mantilla-Morales A, Gallegos-Hernández JF, Posada-Sibaja A. [Histopathologic study of the frontolateral laryngectomy specimen: topics of clinical interest]. *Cir Ciruj*. 2005;73(4):315-8.
16. Buckley JG, MacLennan K. Cancer spread in the larynx: A pathologic basis for conservation surgery. *Head and Neck*. 2000; 22(3):265-74.