

Our Italian experience using lung ultrasound for identification, grading and serial follow-up of severity of lung involvement for management of patients with COVID-19

Luigi Vetrugno MD^{1,2} | Tiziana Bove MD^{1,2} | Daniele Orso MD¹ |
Federico Barbariol MD² | Flavio Bassi MD² | Enrico Boero MD³ |
Giovanni Ferrari MD⁴ | Robert Kong MD, FRCA, EDIC⁵

¹Department of Medicine, Anesthesia and Intensive Care Clinic, University of Udine, Udine, Italy

²Department of Anesthesia and Intensive Care, University-Hospital of Udine, Udine, Italy

³Anesthesia and Intensive Care, San Giovanni Bosco Hospital, Torino, Italy

⁴SC Pneumologia ad Indirizzo Semi Intensivo, Azienda Ospedaliera Ordine Mauriziano, Torino, Italy

⁵Cardiac Anaesthesia & Intensive Care, Brighton & Sussex University Hospital, Brighton, UK

Correspondence

Luigi Vetrugno, MD, Department of Medicine, Anesthesia and Intensive Care Clinic, University of Udine, Via Colugna n° 50, 33100 Udine, Italy.
Email: luigi.vetrugno@uniud.it

Abstract

Lung ultrasound (LU) has rapidly become a tool for assessment of patients stricken by the novel coronavirus 2019 (COVID-19). Over the past two and a half months (January, February, and first half of March 2020) we have used this modality for identification of lung involvement along with pulmonary severity in patients with suspected or documented COVID-19 infection. Use of LU has helped us in clinical decision making and reduced the use of both chest x-rays and computed tomography (CT).

KEYWORDS

COVID-19, interstitial syndrome, lung ultrasound

1 | LUNG ULTRASOUND

During this ongoing battle against the novel COVID-19, LU has quickly been recognized as a tool for diagnosis and monitoring of lung involvement severity.¹

A normal LU demonstrates what are termed A lines. These are a repetition of the pleural line at the same distance from skin to the pleural line. This is indicative of air below the pleural line, corresponding to the parietal pleura. Lines may be complete or partial (Figure 1, Movie S1).

Demonstration of B lines are described as hyperechoic laser-like artifacts that resemble a "comet tail" (Figure 2). These arise from the pleural line and move in concert with a sliding lung. The A lines are generally not present. B1 lines are associated with an interstitial syndrome and diminished lung aeration. B2 lines are confluent lines appearing as a "white lung" (called also glass-rockets), equivalent to

computed tomography (CT) ground-glass opacities. This suggests a more severe loss of lung aeration (Movies S2 and S3).

Lung consolidations (C) are associated with hepatization of lung parenchyma with or without air bronchograms, and suggest major loss of lung aeration (atelectasis vs pneumonia; Movie S4).

We have not identified an ultrasound appearance that would be pathognomonic of COVID-19.²

2 | LUNG ULTRASOUND SCORE

The lung ultrasound score (LUS) has been shown to be a useful tool in intensive care (ICU) patients with adult respiratory distress syndrome (ARDS). We feel that this has been of value in assessing severity of lung involvement with COVID-19.^{3,4}

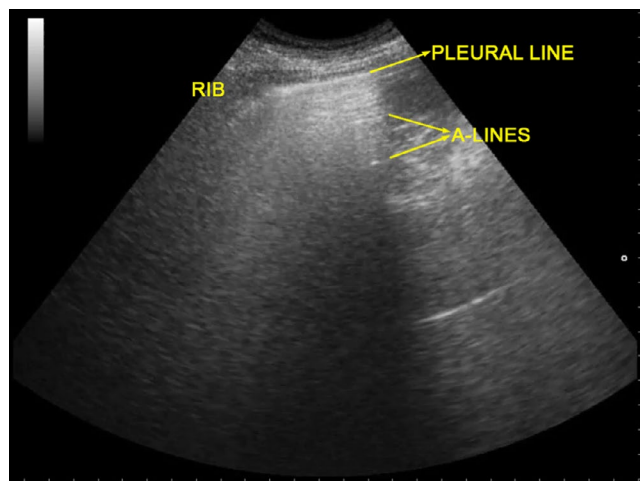


FIGURE 1 Lung ultrasound of normal aerated lung. A lines are visible: they are a repetition of the pleural line at the same distance from skin to pleural line. This indicates the presence of air below the pleural line (which corresponds to the parietal pleura). A lines can be complete or partial (as in this image)

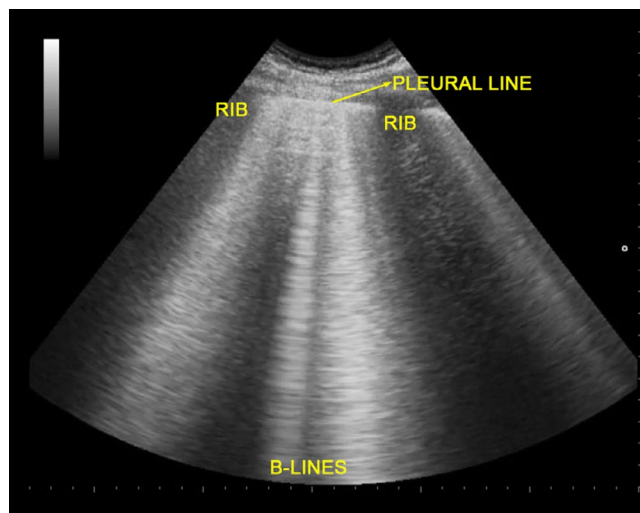


FIGURE 2 Lung ultrasound of interstitial syndrome, characterized by the presence of three or more B lines between two ribs. B lines are hyperechoic laser-like artifacts that resemble a comet tail, arise from the pleural line and move in concert with lung sliding. A lines are wiped out

One may perform a topographic analysis of the underlying lung regions daily without moving the patient. A scan of the three different areas of the thorax: anterior, lateral, and posterior, and then superior and inferior segments are performed. Thus, six specific regions for each lung are defined and categorized by one of four different aeration patterns.

A point scoring system is employed by region and ultrasound pattern as: A = 0 point, B1 = 1 point, B2 = 2 points, C = 3 points. Thus, a LUS of 0 is normal, and 36 would be the worst.

LUS score can be used to follow the clinical patient trajectory in which an increased score means decreased lung aeration, while on

the contrary, a decrease in score means an increase in lung aeration limiting the need of chest x-ray and CT scan.²

An experienced sonographer can do this examination within 5 minutes, while brief training and about 25 supervised exams seem to be sufficient to achieve a basic ability to perform the study.⁵ A prior study showed the impact of LU to affect clinical decisions in up to 50% of intensive care unit patients.⁶

3 | CLINICAL CONTEXT

Although a patient's clinical context allows for an improved pretest estimate of COVID-19 lung involvement, it appears that LU may serve as a bedside tool to improve evaluation of lung involvement, and also reduce the use of chest x-rays and CT.⁷ In addition, several intensive care units following central venous line positioning with ultrasound, have not been routinely obtaining post insertion chest x-rays.^{8,9}

While the ability of a chest x-ray to discriminate a bacterial pneumonia from a non-bacterial infection is no more than 60%,¹⁰ LU has a higher sensitivity (80%).¹¹ Specific comparison studies in critically ill patients regarding viral pneumonia, however, are few.¹²

4 | CONCLUSION

During this pandemic we have used LU in patients suspected or diagnosed with COVID-19. Application of LUS has allowed for identification of patients with lung involvement and severity. In addition, serial studies help us follow for progression or regression of disease.

With the application of LU we have had a noted reduction in use of chest x-rays and CT scans during this pandemic, helping us to make care and management of our patients a little more efficient.

CONFLICT OF INTEREST

Luigi Vetrugno received travel support for Congress Lecture by Cook Medical. The other authors declare no conflict of interest.

AUTHORS' CONTRIBUTIONS

LV and DO: concept, design, and drafting the manuscript. TB, FB, EB, FB, GF: critical revision of the manuscript for important intellectual content. RK and DL: critical review and editing of the manuscript. All authors read and approved the final manuscript.

REFERENCES

1. Peng QY, Wang XT, Zhang LN; Chinese Critical Care Ultrasound Study Group (CCUSG). Finding of lung ultrasonography of novel coronavirus pneumonia during the 2019–2020 epidemic. *Intensive Care Med.* 2020. <https://doi.org/10.1007/s00134-020-05996-6>. [Epub ahead of print]
2. Bouhemad B, Mongodi S, Gabriele V, Rouquette I. Ultrasound for "Lung Monitoring" of ventilation patients. *Anesthesiology.* 2015;122:437–447.

3. Man MA, Dantes E, Domokos Hancu B, et al. Correlation between transthoracic lung ultrasound score and HRCT features in patients with interstitial lung diseases. *J Clin Med*. 2019;8(8):E1199.
4. Zhao Z, Jiang L, Xi X, et al. Prognostic value of extravascular lung water assessed with lung ultrasound score by chest sonography in patients with acute respiratory distress syndrome. *BMC Pulm Med*. 2015;15:98.
5. Rouby JJ, Arbelot C, Gao Y, et al. Training for lung ultrasound score measurement in critically ill patients. *Am J Respir Crit Care Med*. 2018. <https://doi.org/10.1164/rccm.201802-0227LE>. [Epub ahead of print].
6. Xirouchaki N, Kondili E, Prinianakis G, et al. Impact of lung ultrasound on clinical decision making in critically ill patients. *Intensive Care Med*. 2014;40:57–65.
7. Brogi E, Bignami E, Sidoti A, et al. Could the use of bedside lung ultrasound reduce the number of chest x-rays in the intensive care unit? *Cardiovasc Ultrasound*. 2017;15:23.
8. Smit JM, Haaksma ME, Lim EHT, et al. Ultrasound to detect central venous catheter placement associated complications: a multicenter diagnostic accuracy study. *Anesthesiology*. 2020;132:781–794.
9. Vetrugno L, Bove T, Orso D, Flabio B, Boero E, Ferrari G. Lung ultrasound and COVID-19 “pattern”: not all that glitters today is gold tomorrow. *J Ultrasound in Med*. (Accepted for publication).
10. Courtoy I, Lande AE, Turner RB. Accuracy of radiographic differentiation of bacterial from nonbacterial pneumonia. *Clin Pediatr (Phila)*. 1989;28(6):261–264.
11. Berce V, Tomazin M, Gorenjak M, Berce T, Lovrenčić B. The usefulness of lung ultrasound for the aetiological diagnosis of community-acquired pneumonia in children. *Sci Rep*. 2019;9(1):17957.
12. Testa A, Soldati G, Copetti R, Giannuzzi R, Portale G, GentiloniSilveri N. Early recognition of the 2009 pandemic influenza A (H1N1) pneumonia by chest ultrasound. *Crit Care*. 2012;16(1):R30.

SUPPORTING INFORMATION

Additional supporting information may be found online in the Supporting Information section.

Movie S1. Anterior region with A lines.

Movie S2. Posterior region with coalescent B lines.

Movie S3. A thickened and disrupted pleural line with B lines.

Movie S4. A subpleural consolidation disappearing with inspiration.

How to cite this article: Vetrugno L, Bove T, Orso D, et al.

Our Italian experience using lung ultrasound for identification, grading and serial follow-up of severity of lung involvement for management of patients with COVID-19.

Echocardiography. 2020;00:1–3. <https://doi.org/10.1111/echo.14664>